



HAL
open science

**EGFR, p16INK4a and E-cadherin
immuno-histochemistry and EGFR point mutations
analyses in invasive cervical cancer specimens from
Moroccan women.**

W. El Hamdani, M. Amrani, M. Attaleb, N. Laantri, M. M. Ennaji, M.
Khyatti, M. El Mzibri

► **To cite this version:**

W. El Hamdani, M. Amrani, M. Attaleb, N. Laantri, M. M. Ennaji, et al.. EGFR, p16INK4a and E-cadherin immuno-histochemistry and EGFR point mutations analyses in invasive cervical cancer specimens from Moroccan women.. Cellular and Molecular Biology, 2010, 56 Suppl, pp.OL1373-1384. 10.1170/157 . pasteur-00641652

HAL Id: pasteur-00641652

<https://riip.hal.science/pasteur-00641652>

Submitted on 16 Nov 2011

HAL is a multi-disciplinary open access archive for the deposit and dissemination of scientific research documents, whether they are published or not. The documents may come from teaching and research institutions in France or abroad, or from public or private research centers.

L'archive ouverte pluridisciplinaire **HAL**, est destinée au dépôt et à la diffusion de documents scientifiques de niveau recherche, publiés ou non, émanant des établissements d'enseignement et de recherche français ou étrangers, des laboratoires publics ou privés.



EGFR, p16^{INK4a} AND E-CADHERIN IMMUNO- HISTOCHEMISTRY AND EGFR POINT MUTATIONS ANALYSES IN INVASIVE CERVICAL CANCER SPECIMENS FROM MOROCCAN WOMEN

W. EL HAMDANI^{1,2,3}, M. AMRANI², M. ATTALEB¹, N. LAANTRI³, M.M. ENNAJI⁴,
M. KHYATTI³ AND M. EL MZIBRI¹✉

1 Unité de Biologie et recherché Médicale, Centre National de l'Energie, des Sciences et Techniques Nucléaires, Maroc

2 Service d'Anatomie Pathologique. Institut National d'Oncologie, Rabat. Maroc

3 Laboratoire d'Oncologie, Institut Pasteur du Maroc, Casablanca, Maroc

4 Laboratoire de Virologie, Hygiène & Microbiologie, Faculté des Sciences et Techniques Mohammedia, Maroc

Unité de Biologie et Recherche Médicale

Centre National de l'Energie, des Sciences et des Techniques Nucléaires B.P. 1382 RP, 10001 Rabat, Maroc.

Tel: +212-37-71.27.51, Fax: +212-37-71.18.46, E-mail: mzibri@yahoo.com, elmzibri@cnesten.org.ma

Received May 18th, 2010; Accepted July 30th, 2010; Published August 10th, 2010

Abstract – The involvement of human papillomavirus in the development of cervical cancer has been firmly established. However, better management of cervical cancer rests on good diagnosis and an effective therapy. In this study we evaluated the frequency of point mutations in epidermal growth factor receptor (EGFR) for future use of tyrosine kinase inhibitors in clinical treatment and to assess the use of EGFR, p16^{INK4a} and E-cadherin as biomarkers in cervical cancer diagnosis with immunohistochemistry. Fifty-three patient specimens of cervical cancer were analysed for HPV infection, for EGFR mutations in exons 18 through 21, and for expression of EGFR, p16^{INK4a} and E-cadherin by immunostaining. Results showed that 79.24% of the cases (42/53) are HPV positive and the HPV types more closely associated with risk are HPV 16 and 18. In all 53 analysed specimens, any mutation affecting the EGFR kinase domain in exons 18 through 21 was observed. Expressions of EGFR, p16^{INK4a} and E-cadherin were detected in 88,67% (47/53), 92,45% (49/53) and 79,24% (42/53) of analysed specimens respectively. Thus, EGFR, p16^{INK4a} and E-cadherin would be excellent tools for IHC analysis during the cervical cancer development. EGFR and p16^{INK4a} can be used for early diagnosis and E-cadherin for cancer progression and cell migration. However, treatment of cervical cancer with TKIs may not be effective and the identification of other EGFR inhibitors is needed.

Key words: Cervical cancer, HPV, EGFR, p16^{INK4a}, E-cadherin, mutation analysis, Immunohistochemistry.

INTRODUCTION

Cisplatin (cisplatinum or cis- Worldwide, cervical cancer is a major female malignancy, being the fifth common cancer and the second leading cause of cancer-related death in women (61). In Morocco, cervical cancer is the second most frequent female cancer after breast cancer and represents a major public health problem with an estimation of 6000 cases/year. Among them, only 2250 cases are successfully treated. The National Institute of Oncology (INO) hospital-based cancer registry data reports that more than 500 new cases are diagnosed annually and only 5% were in stages I and II, whereas the great majority were in advanced stages (3, 4, 16).

In Morocco, the national program against cervical cancer is exclusively based on the cytology and immunohistology screening that

offer substantial protection although current coverage is low; whereas, cervical cancer treatment that focuses on the utilisation of concomitant platinum-based therapy with radiation protocols remains the standard care for patients with invasive cervical disease (4). There is a clear need for novel, more effective therapeutic strategies and predictive biological markers to improve overall survival and the quality of life for advanced, recurrent and disseminated cervical cancer.

The Epidermal Growth Factor Receptor (EGFR) is a membrane tyrosine kinase receptor that regulates multiple functions (cell growth, differentiation, gene expression and development), contributes to growth activity and tumor survival, and therefore, is a therapeutic target in several tumors (6). Mutations in EGFR gene have been identified and the EGFR

expression was affected in many types of cancer (8, 64, 67). Actually, more than 10 EGFR-targeting agents are in advanced clinical development for the treatment of various human cancer types (21, 22, 51, 58). However, the interest is focused on 4 products, two anti-EGFR monoclonal antibodies (cetuximab and panitumumab) and two small-molecule, reversible EGFR tyrosine kinase inhibitors (gefitinib and erlotinib) that have been approved in several countries for the treatment of metastatic non-small-cell lung cancer (NSCLC), colorectal cancer, squamous-cell carcinoma of the head and neck, and pancreatic cancer (28, 32, 37, 52). Gefitinib and erlotinib have demonstrated long-lasting responses in a subpopulation of NSCLC patients who were found to have specific functional EGFR mutations in exons 18 through 21 (59, 60).

Human papillomavirus (HPV) are considered the major infectious etiologic agents of cervical precancerous lesions and cancers (12). Several studies have shown that HPV E6 and E7 oncoproteins increase the expression and the activation of the EGFR (2) and that E5 protein stimulates recycling of EGFR to the cell surface (71). The E5 gene has been also linked to the expression of EGFR by abrogating degradation of the receptor via inhibition of the endosomal proton-ATPase (70). Therefore, oncogenic HPV could induce upregulation of the EGFR network and cause constitutive activation of this pathway in cervical cancer cells (70). There is evidence that alterations in EGFR expression may play a role in cervical carcinogenesis. However, notwithstanding the established association between EGFR and HPV oncoproteins in cervical cell lines, EGFR overexpression was not correlated to HPV infection in cervical precancerous lesions and invasive cancers (17, 39).

p16^{INK4a} and E-Cadherin are two important proteins used as immunohistochemical markers in various gynaecological cancers. p16^{INK4a}, the product of *CDKN2A* gene is a component of p16^{INK4a}-Cdk4-6/CyclinD-pRb signalling pathway and is perturbed in many cancers. In these tumours, the functions of p16^{INK4a} may be lost due to mutations or suppression of its transcription by promoter methylation (30). In high risk-HPV positive cervical cancer, the oncogene E7 disrupts pRb/E2F interaction, releases active E2F and induces the pRb degradation (45). The existence of the regulatory feedback in the pRb/p16 pathway leads to an

overexpression of p16^{INK4a} in cervical tumours (36). Klaes *et al.* (41) have shown that overexpression of p16^{INK4a} is a specific marker for dysplastic and neoplastic epithelial cells in the cervix. They have clearly demonstrated that use of p16^{INK4a} immunostaining allows precise identification of cervical lesions and significantly reduce false-negative and -positive interpretation in cervical cancer screening (41). Recently, several studies have shown high sensitivity and specificity of p16 based cytology to detect high grade cervical intraepithelial neoplasia (CIN) (74).

E-cadherin is a transmembrane glycoprotein encoded by *CDH1* gene. It is localised on the surface of epithelial cells and mediates adhesion through Ca²⁺-dependent homotypic binding. Based on its biological functions, E-cadherin is regarded as an invasion and metastasis suppressor. Loss of E-cadherin expression or function correlates with increased invasiveness and metastasis in carcinomas of several anatomical sites (24, 31). E-cadherin-mediated cell adhesion system is inactivated by multiple mechanisms. It may be inactivated as a result of genetic alteration, reduced gene expression, changes of other cadherin-catenin complexes or posttranslational modification of the protein leading to cytoplasmic delocalization (34, 47). The expression of E-cadherin is impaired as squamous intraepithelial lesions progress to squamous cervical carcinoma (14). In cervical cancer, the presence and localisation of cytoplasmic E-cadherin were significantly correlated with CIN grade. In invasive types, the expression of E-cadherin was significantly reduced (22) and this is mainly due to gene silencing by methylation processes (18).

This study was planned to evaluate the expression of EGFR, p16^{INK4a} and E-cadherin by immunohistochemistry (IHC) in 53 invasive cervical carcinomas as markers for cervical cancer diagnosis. Moreover, this study was focused on the detection of EGFR mutations, using PCR and sequencing, for exploring future use of TKIs in the treatment of cervical cancer.

MATERIALS AND METHODS

Study subjects

Fifty three paraffin-embedded uterine cervix biopsies were collected at the "Institut National d'Oncologie" (INO) in Rabat, Morocco. The mean age of the patients was 51 with the range 31- 84. Pathological diagnosis was made using the routine hematoxylin-eosin stain on 5µm paraffin sections (26). Epidemiologic data (age, smoking habits and alcohol) and clinical data (tumor stage and size,

histopathological diagnosis, treatment and survival) were obtained from the archives of the Anatomy pathology department at INO in an anonymous fashion.

Paraffin-embedded tissue microdissection and processing

Microdissection analysis was done blindly, without the knowledge of clinical information. Briefly, for each patient three sections of 4 µm paraffin-embedded tumour tissue were placed over silenized slides for IHC labelling (for p16^{INK4a}, E-cadherin and EGFR). Other sections of 10 µm were prepared for DNA extraction.

DNA extraction

DNA from each of the selected specimens was extracted using the MagneSil[®] Genomic, Fixed Tissue System kit (Promega), according to the manufacturer's protocol. The concentration of DNA was then quantified by UV spectrophotometer.

The quality of extracted DNA was controlled by PCR amplification of a fragment of the *β-globin* gene using the primers PC04 and GH20 (Table I) which gives a fragment of 265 bp.

HPV detection and typing

DNA amplification: DNA was amplified by PCR using consensus primers: MY09 and MY11 (Table I). Amplification reaction was performed in a total volume of 50 µl. The amplification mixture contained 50 pmol of each consensus primer, 200 µM of each dNTP (dATP, dCTP, dGTP, and dTTP), 0.625 units of Taq DNA polymerase, and 3 µl of DNA specimen in 1×Taq polymerase buffer. The mixture was first denatured at 94°C for 7 minutes, followed by 35 cycles of PCR with denaturation at 94°C for 30s, primer annealing for 1 min at 52°C and primer extension for 1 min 30s at 72°C. At the end of the last cycle, the mixture was incubated at 72°C for 7 min. For every reaction, negative control without DNA template was used and DNA extracts from SiHa and CaSki cervical cancer cell lines were used as a positive control.

Hybridisation analysis of PCR products

Aliquots of 10 µl of the PCR product were analysed by electrophoresis on 2% agarose gel. The 50 bp ladder molecular-weight marker was included for detection of the size of the DNA amplification product.

PCR products were transferred onto a Hybond N⁺ membrane (Amersham) by Southern blotting. The membrane was prehybridized at 37°C for at least 2 h in hybridization buffer containing SSC buffer, Denhart's solution, and sodium dodecyl sulphate (65). Biotin labelled probes were added and allowed to hybridize overnight at 37°C. The probes used in this study were the oligonucleotides MY14, WD74, WD126, MY16, MY115 and MY70 (Table I) which are the specific probes corresponding respectively to the HPV 16, 18, 31, 33, 35 and 45 genotypes (9).

After washing the membrane under stringent conditions (2 times in 20 ml of SSC 2X solution at room temperature for 5 min, 2 times in 20 ml of a solution containing SSC 2X and SDS 1% at 40°C for 5 min and 2 times in 20 ml of a solution containing SSC 0.2X/ and SDS 0.1% at 40 °C for 5 min) (3), hybrids were revealed using the biotin luminescence detection kit according to the manufacturer's instructions (Biolabs, England). Finally, membranes were exposed for 30 min to X-ray film (Hyperfilm ECL, Amersham).

EGFR point mutations analysis

Genetic analysis of the EGFR gene was performed by PCR amplification of exons 18, 19, 20 and 21, that are the more frequent mutated regions in cancers, and direct sequencing of the PCR products. Briefly, DNA was amplified in a total volume of 25 µl, containing 1.5 mM MgCl₂, 200 µM of each dNTP (dATP, dCTP, dGTP, and dTTP), 300 nM of each primer, 0.3 units Taq DNA polymerase, and 2 µl of DNA in 1X Taq buffer. The primers used to amplify exons 18 to 21 of EGFR gene are listed in Table II. DNA was first denatured at 95°C during 3 minutes, followed by 35 cycles of PCR with denaturation at 94°C for 30s, primer annealing for 1 minute at 60°C and primer extension for 1 minute at 72°C. At the end of the last cycle, the mixture was incubated at 72°C for 10 min. PCR products were purified using the Magnesil yellow solution (Promega) to eliminate the primers used for PCR reactions, then the sequence reaction for each purified product was carried out in thermocycler. The sequencing reaction was performed in a final volume of 20 µl containing 20 pmol of one primer (forward or reverse), 3 µl of Big Dye (version 1.1), and 2 µl of purified PCR product. Twenty-five cycles were performed: denaturation at 96°C for 10s, primer annealing at 55°C for 10s and extension at 60°C for 4 min. To eliminate the excess of labelled ddNTPs, sequencing reaction products were purified using the Magnesil green solution. Direct sequencing of amplified PCR products was performed on an ABI PRISM sequencing apparatus (ABI Prism 310 Genetic Analyser, Applied Biosystem). The sequence alignments were done with the BioEdit Sequence Alignment Editor and analyzed using SeqScape software v2.5 (Applied Biosystems).

Immunohistochemical analysis

Immunohistochemistry was performed on the tissue sections using the peroxidase-anti-peroxidase protocol as described previously (77). Briefly, the slides were immersed in xylene to remove the paraffin, hydrated through graded ethanol solution and the endogenous peroxidase activity removed with 3% H₂O₂ for 30 min. The sections were then incubated with 10% normal goat serum (NGS) in TGS buffer at room temperature for 30 min to prevent non-specific binding, then for 40 min with each primary antibody.

Antibodies used were: anti-EGFR H11 (DakoCytomation, dilution 1/45, proteinase K treatment), E-cadherin (clone NCH-38; DakoCytomation, dilution 1/100, citrate treatment in pH 6), and a ready-to-use p16^{INK4a} kit (clone E6H4, K5334, DakoCytomation). After incubation with specific secondary antibody and peroxidase-anti-peroxidase complex formation, reactivity was detected using the 3, 3'-diaminobenzidine (DAB) as chromogen. Positive and negative controls were available for all cases.

Evaluation of immunostaining results

Results were interpreted using a conventional light microscopy. A representative immunohistochemical staining of EGFR, p16^{INK4a} and E-cadherin in epidermoid carcinomas samples were showed in Figure 1. As a control, immunostaining of E-cadherin in normal epithelium was also included (Figure 1).

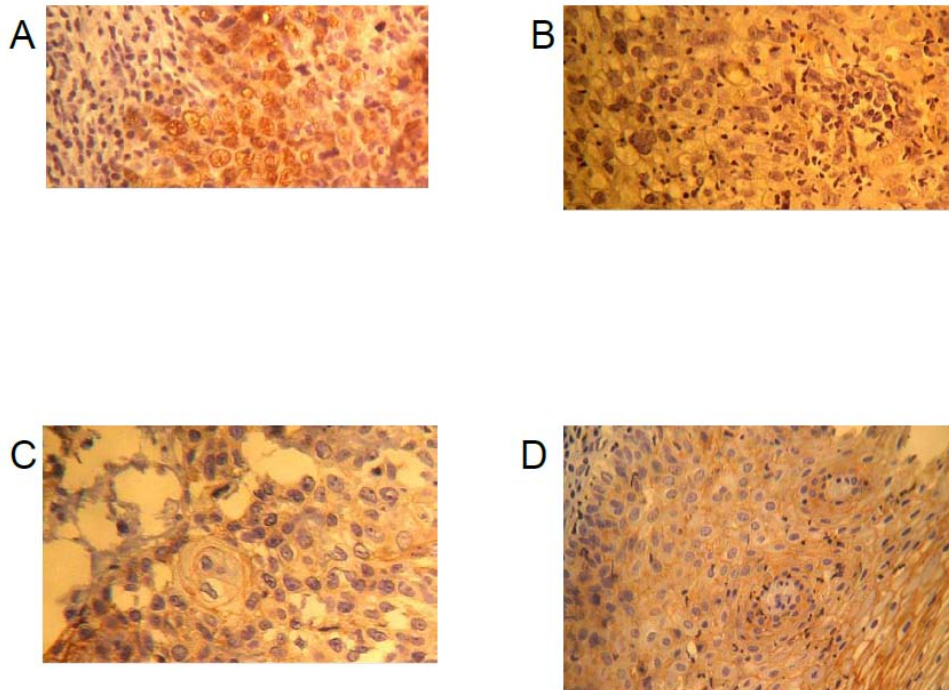
EGFR: The staining results for EGFR were scored semi-quantitatively. Only clear staining of the tumour cell membranes were considered positive. Immunoreactivity was quantified by scoring the intensity of staining; negative or weak when less than 50% of cells are stained, moderate

Table 1. List of primers and specific probes used in HPV detection and typing (9)

		Sequences	
Primers for β -globin amplification	PC 04	5' CAA CTT CAT CCA CGT TCA CC	3'
	GH 20	5' GAA GAG CCA AGG ACA GGT AC	3'
Primers for HPV amplification	MY 09	5' CGT CCM ARR GGA WAC TGA TC	3'
	MY 11	5' GCM CAG GGW CAT AAY AAT GG	3'
	MY14	5' CAT ACA CCT CCA GCA CCT AA	3'
	WD74	5' GGA TGC TGC ACC GGC TGA	3'
Specific probes for HPV typing	WD126	5' CAA AAG CCC AAG GAA GAT C	3'
	MY16	5' CAC ACA AGT AAC TAG TGA CAG	3'
	MY115	5' CTG CTG TGT CTT CTA GTG ACA G	3'
	MY70	5' TAG TGG ACA CTA CCC GCA G	3'

Table 2. Primers used to amplify EGFR exons 18 through 21 (73)

Exon	Primers	Sequences	PCR product size
18	EGFR18F	5' CAA ATG AGC TGG CAA GTG CCG TGT C	3'
	EGFR18R	5' GAG TTT CCC AAA CAC TCA GTG AAA C	3'
19	EGFR19F	5' GCA ATA TCA GCC TTA GGT GCG GCT C	3'
	EGFR19R	5' CAT AGA AAG TGA ACA TTT AGG ATG TG	3'
20	EGFR20F	5' CCA TGA GTA CGT ATT TTG AAA CTC	3'
	EGFR20R	5' CAT ATC CCC ATG GCA AAC TCT TGC	3'
21	EGFR21F	5' CTA ACG TTC GCC AGC CAT AAG TCC	3'
	EGFR21R	5' GCT GCG AGC TCA CCC AGA ATG TCT GG	3'

**Figure1.** Representative immunohistochemical staining in epidermoid carcinoma samples and control. A) Intense Nuclear staining of p16^{INK4a}, B) Faint cytoplasmic and membranous staining of EGFR, C) Moderate Membranous staining of E-cadherin and D) immunostaining of E-Cadherine in normal epithelium. (magnification X40).

when stained cells represent 50 to 80 %, and strong for more than 80 % of total cells.

p16^{INK4a}: For the quantitative evaluation of p16^{INK4a} staining, the percentage of positive cells was recorded and classified according to nuclear and cytoplasmic staining. p16^{INK4a} nuclear staining with or without cytoplasmic staining was regarded as positive, and percentage of positive cells was calculated. Immunoreactivity to p16^{INK4a} is classified in 3 groups according to the percentage of stained cells; weak, variable and strong corresponding respectively to less than 5% of the cells, 5–50% of the cells (containing weak and strong areas of intensity), and more than 50% of the cells stained for p16^{INK4a}.

E-cadherin: E-cadherin is revealed in cytoplasm, cellular membrane and nucleus. The staining is considered negative when the cell staining is less than 10%, weak 10-50 %, intermediate 50-80 % and strong more than 80 %.

Statistical analysis

Statistical analyses were performed using Medcalc version 11.3.3 software that uses directly the chi-square trend test. The associations between the discrete variables were assessed using chi-square test. Differences were considered statistically significant for $P \leq 0.05$.

RESULTS

Anatomy pathology analyses

Histologically, the 53 cervical cancer biopsies were classified as follows: 51 epidermoid carcinomas, one mucinous adenocarcinoma and one adenosquamous carcinoma. Clinical stages of cervical cancers were classified according to the International Federation of Gynaecology and Obstetrics (FIGO) classification. The phenotypic distribution of the 53 cervical cancers showed that the majority of cases (96.83%) were diagnosed at advanced stages (IIB and IIIB), whereas only 3.13% of patients were admitted at an earlier stage (IB).

HPV testing

Using PCR amplification combined with molecular probing, we revealed the presence of HPV DNA in 79.2% of cases (42/53) with a predominance of HPV 16 and 18. All HPV positive specimens were positive for high-risk types.

The distributions of viral genotypes in the 42 cervical cancer HPV positive cases are reported in Table III. Molecular typing showed single and multiple infections. HPV 16, 18 and 31, alones or in co-infections, were presents respectively in 76.2% (32/42), 38.1% (16/42) and 23.8% (10/42) of cases, whereas the others genotypes showed a low prevalences. Multiple HPV infections were detected in 25 of the 42 HPV positive specimens (59.52%). Among the

multiple infection's cases, the most commons were 16/18 and 16/31 (8 cases each).

Table 3. Distribution of HPV genotypes in the 53 cervical cancer samples.

HPV types	No. (%)
Single	
16	10 (23.8)
18	5 (9.52)
45	2 (4.76)
Total single infection	17
Double	
16 + 18	6 (14.28)
16 + 31	6 (14.28)
16 + 35	3 (7.14)
16 + 45	3 (7.14)
18 + 31	1 (2.38)
18 + 45	1 (2.38)
Total double infection	20
Triple	
16 + 18 + 33	2 (4.76)
16 + 31 + 33	1 (2.38)
18 + 31 + 33	1 (2.38)
16 + 31 + 45	1 (2.38)
Total triple triple	5
Total HPV infection	42

EGFR mutations in cervical cancer specimens

Many hot point mutations in exons 19 through 21 in EGFR gene were associated with a long-lasting response to treatment with some active tyrosine kinase inhibitors, e.g., gefitinib and erlotinib. Thus, in this study, we have focused our interest on mutations in theses exons. The figure 2 shows an example of nucleotide sequence of EGFR exon 19 and 21 obtained in cervical cancer specimen. Theses regions are frequently deleted and mutated in lung cancer. Direct sequencing analysis of exons 18, 19, 20, and 21 didn't show any mutation in any cervical cancer specimen.

Immunohistochemistry analyses

EGFR expression

The percentage of cells with the highest intensity staining ranged widely from 1% to 100%. The majority of analysed specimens (47/53) showed high expression of EGFR. Among them, 61.7 % (29/47) expressed moderate EGFR level whereas highly EGFR expression was observed in 38.2% (18/47) of cases. In latter cases, membranous and cytoplasmic staining occurred in more than 50% of cells. Moreover, no correlation between EGFR expression and cervical tumour stage was observed ($p=0.5$).

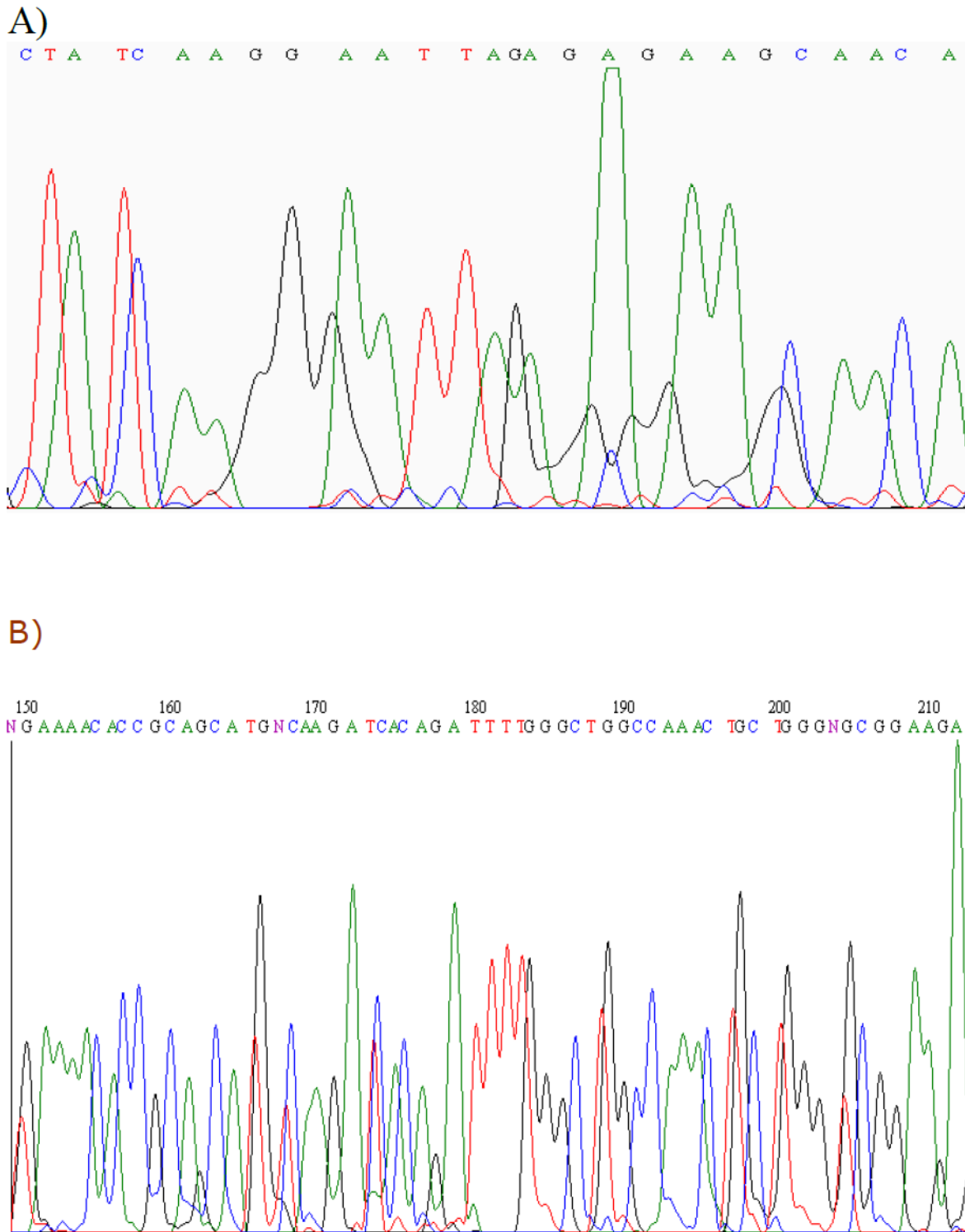


Figure 2. Example of sequence results of EGFR in exon 19 (A) and exon 21 (B). **A)** exon 19 containing the 2235-2254 region more frequently deleted and mutated in Lung cancer. **B)** exon 21 without mutation at position 2573T>G (L858R) frequently found in lung cancer.

p16^{INK4a} expression

The overall positivity rate for p16^{INK4a} was ranged between 0 and 100% of the entire lesion. Immunoreactivity to p16^{INK4a} was found in 49 of the 53 cases (92.4%). Among them, 45 cases (91.8 %) showed both nuclear and cytoplasmic staining, while 4 cases showed predominantly cytoplasmic staining (8.1%).

The intensity was related to the percentage of positive staining and the majority of biopsies expressed high levels. In fact, 56.58% of cases had more than 80% of cells expressing high levels of p16^{INK4a}. Moreover, no correlation between p16^{INK4a} expression and cervical tumour stage was observed (p=0.3587).

E-cadherin expression

42 of the 53 cases expressed E-cadherin and immunostaining was observed in all cellular compartments. Among the 42 invasive cervical carcinomas, membrane expression of E-cadherin was detected in 4 cases (9.5%) and cytoplasmic expression in only one case (2.4%). Simultaneous immunostaining at the membrane and the cytoplasm was found in more than 76% of cases (32 cases); whereas, simultaneous immunostaining of the nucleus and the cytoplasm expression was rarely observed (9.5%). Moreover, statistical analysis didn't show any correlation between E-cadherin expression and cervical tumour stage (p=0.214).

DISCUSSION

Epidemiological and clinical studies have shown that HPV is a principle ethiological factor in cervical cancer development. To date, more than 200 genotypes have been reported but the interest was focused on genital HPVs that are associated with epithelial neoplasms ranging from benign common warts to malignant carcinoma of the uterine cervix (12). In this study, the prevalence rate of HPV infection was 79.2% which is within the reported range among women with cervical cancer from Morocco. Recent epidemiological prevalence studies in Morocco, using PCR to detect HPV DNA, have shown a range from 62%- 92% (3, 50). These results may reflect differences in HPV detection sensitivity, due to the difference of sampling, storage, and fixation protocols, rather than HPV unrelated cancers. Viral distribution showed a predominance of HPV 16 and 18. Worldwide, HPV 16 is the most common type followed by the HPV 18 and geographical variations in non-

HPV 16 distribution have been noted (29, 38). Bosch *et al.* (13) established that globally 50% of cervical cancer specimens contained HPV 16 in African countries. On the other hand, co-infection with multiple HPV types is a common finding, of many molecular epidemiological studies. Some HPV types might interact or act synergistically to induce lesion development or progression (72). Our results indicate that among the 42 HPV positive cases, 25 (59.52%) were infected with 2 or 3 HPV genotypes, and therefore, corroborate that multiple HPV infection is likely to be associated with the development of cervical neoplasia. Previous studies have shown that multiple infections differ considerably between clinical groups and in relation to the HPV detection assays used. In Morocco, a previous study showed that co-infection occurred in 35.5% of HPV positive cases (50). Worldwide, several studies have shown that multiple infections are present in 3.7% in Thailand (19), 5.1% in Brazil (25), 9% in the Philippines (56), 12.9% in Peru (66), 19.3% in Paraguay (63) and 32% in Costa Rica (33).

Over the last two decades, epidemiologic and experimental data has confirmed that abnormal EGFR expression or signalling play a critical role in human tumor development (5). EGFR has emerged as a leading target for the treatment of patients with NSCLC and specific mutations in the *EGFR* gene may identify lung cancer patients with a good response to the tyrosine kinase inhibitor (59, 60). The overexpression of EGFR in a wide variety of solid tumours, including cervical cancer (57) prompted us to look for the presence of mutations in exons 18 through 21 in cervical cancer specimens from Moroccan women. Direct sequencing analysis of the 4 exons showed the absence of mutations affecting the EGFR TK domain in all cervical cancer specimens. This result is congruent with a recent study reporting that mutations in the EGFR kinase domain are very rare in squamous intraepithelial lesions and cervical cancer. Arias-Pulido *et al.* (5) have reported the absence of EGFR mutations in exons 19 and 21 in 89 human neoplastic specimens from USA. Analysis of 889 tumours, including colorectal (n=391), gastric (n=185), breast (n=73), acute leukemia (n=88), glioblastoma (n=59) and hepatocellular (n=73) tumour specimens showed the presence of EGFR mutations in one breast, one colorectal and one glioblastoma cancer sample (7), suggesting that

EGFR mutations are rare or occur at a very low frequency in these solid tumours. This is in contrast to patients with lung cancer who show a high frequency (80%) of EGFR TK domain mutations (46). Since our results indicate that EGFR mutations are uncommon in invasive cervical cancer, treatment with TKI (gefitinib or erlotinib) will unlikely to be effective in these patients and, targeting the EGFR with other strategies should be more appropriate. Furthermore, inhibiting EGFR with monoclonal antibodies may be more effective than EGFR specific TKI treatment in cervical cancer patients, and clinical trials with these agents are underway (35). In fact, addition of the cetuximab, a monoclonal antibody, to cervical HeLa cell line caused 53% growth inhibition (35). Moreover, Bellone *et al.* (10) demonstrated that cervical cancer cell lines derived from primary and recurrent tumours were very sensitive to cetuximab-mediated antibody-dependent cellular cytotoxicity and cetuximab-mediated inhibition of tumour growth.

EGFR deregulation may also include increased co-expression of receptor ligands (EGF, TGR alpha); gene amplification, activating EGFR mutations (EGFRvIII), heterodimerization and crosstalk with other members of the EGF receptor family, as well as interaction with other cell signalling systems and viral proteins (21). EGFR can be evaluated in different ways: quantification of the receptor at the DNA, RNA or protein levels, or assessment of the degree of signalling from the receptor through analysis of receptor activation or the activation of downstream markers (21). In cervical cancer, HPV proteins seem to have an important role in EGFR expression resulting in an increase of EGFR recycling and over-expression (35, 68, 71, 76). Because of the genomic instability induced by HPV, it was important to evaluate EGFR expression in cervical cancer specimens from Moroccan women.

Immunohistochemistry (IHC) is commonly used to evaluate EGFR protein levels and is arguably the most convenient method for analysing clinical specimens. Using IHC, we showed that more than 86% (47/53) of cervical cancer cases revealed moderate and strong EGFR expression. Many studies have looked at the level of EGFR expression as a prognostic factor. Published data showed that although normal cervical epithelium did not show appreciable staining for EGFR, low-grade and high-grade

squamous intraepithelial lesions (HG-SIL) (11, 15, 23, 48) and invasive CC has elevated levels of EGFR (27, 39, 40, 42, 43, 49). Reported EGFR over-expression varied over a wide range from 6-100% and in the majority of these studies, increased EGFR expression was associated with reduced recurrence-free or overall survival rates. However, other studies did not find such association (44, 54, 55). These conflicting results might be related to the population size and the techniques employed to assess EGFR staining.

Because of significant inter- and intraobserver variability in interpreting both Pap smears and the relatively low sensitivity of Pap smears, there is a need for better biomarkers to enhance diagnosis of cervical neoplasia (69, 75). Many studies have analyzed the presence of p16^{INK4a} in cervical neoplasia and have found a relationship between p16^{INK4a} expression, high-risk HPV types and cervical neoplasia; raising hope that p16^{INK4a} could represent a specific and sensitive marker for cervical neoplasia (41, 53, 62). Analysis of p16^{INK4a} staining by IHC in the 53 cervical cancer biopsies showed that 92.4% (49/53) had high level of p16^{INK4a} expression with a predominance of both nuclear and cytoplasmic staining. Our results point out that p16^{INK4a} overexpression does not seem to be exclusively induced by the presence of HPV and other mechanisms may be involved. These findings are in agreement with results obtained by Klaes *et al.* (41) showing that 58 of 60 invasive cervical carcinomas expressed p16^{INK4a}. Additionally, Agoff *et al.* (1) reported a lower frequency of p16^{INK4a} expression both in invasive squamous carcinomas (91%) and in adenocarcinomas (71%).

In this study, no correlation between p16^{INK4a} expression and tumour stage was observed. p16^{INK4a} is a negative regulator of the cell cycle and its expression might have an inverse correlation with tumour stage. Thus, the absence of correlation may be due to the limited number of cases in various cervical cancer stages in our specimens.

In this study, IHC analysis showed that E-cadherin is moderately expressed in about 85% (45/53) of informative cases with reduced membranous and cytoplasmic localization in 95.5% of the cases (43/45). E-cadherin plays a pivotal role in maintenance of normal adhesion in epithelial cells but has also been shown to suppress tumour invasion and participate in cell signalling (24, 31). In squamous cervical epithelium, E-cadherin is predominantly found at

the cell-to-cell borders in the basal and parabasal cell layers. While in squamous metaplasia, E-cadherin is heterogeneously expressed throughout the epithelial thickness, prominently in the basal and parabasal layers (14). Our results indicated that E-cadherin expression did not correlate with HPV status. This is in agreement with other studies reporting that HPV infection does not affect E-cadherin expression (14).

In conclusion, cervical cancer development is closely related to HPV infection and persistence. In high-risk HPV infected cervical cancer specimens, EGFR and p16^{INK4a} are over-expressed. Therefore, EGFR and p16^{INK4a} based IHC could be used as biomarkers for cervical cancer diagnosis. Over-expression of E-cadherin will be of great interest to predict potential cancer cell migration and prevent cancer evolution to metastasis. Thus, EGFR, p16^{INK4a} and E-cadherin are excellent tools for IHC analysis during the cervical cancer development. Therefore, combination of cytohistological diagnosis, IHC evaluation and HPV testing will improve cervical cancer diagnosis and management. On the other hand, since no mutations affecting the EGRF kinase domain were found in exons 18 through 21, treatment of cervical cancer with TKIs may not be effective, and targeting the EGFR with other strategies may be more suitable.

Acknowledgements - This study was supported in part by the WHO EMRO and COMSTECHE grant (RAB&GH 06-07_28). Special thanks to the technical staff from CNESTEN and INO for their excellent technical assistance. Special thanks to Dr. Khalid El Kari for statistical analyses.

REFERENCES

- Agoff, N., Lin, P., Morihara, J., Mao, C., Kiviat, N.B. and Koutsky, L.A. 2003. p16INK4a Expression Correlates with Degree of Cervical Neoplasia: A Comparison with Ki-67 Expression and Detection of High-Risk HPV Types. *Mod Pathol.* 2003, **16**(7): 665–673
- Akerman, G.S, Tolleson, W.H, Brown, K.L., Zyzak L.L, Mourateva, E., Engin, T.S., Basaraba, A., Coker, A.L., Creek, K.E. and Pirisi, L. Human Papillomavirus Type 16 E6 and E7 Cooperate to Increase Epidermal Growth Factor Receptor (EGFR) mRNA Levels, Overcoming Mechanisms by which Excessive EGFR Signaling Shortens the Life Span of Normal Human Keratinocytes. *Cancer Res* 2001, **61**(9): 3837-3843.
- Amrani, M., Lalaoui, K., El Mzibri, M., Lazo, P. and Belabbas, M.A. Molecular detection of human papillomavirus in 594 uterine cervix samples from Moroccan women (147 biopsies and 447 swabs). *J. Clin. Virol.* 2003, **27**(3): 286-95.
- Amrani, M., Lalaoui, K., El Mzibri, M., Rouas, L., Benkirane, L., Lamaalmi, N., Regragui, A., Gamra, L. and Belabbas, M.A. Molecular typing of Human papillomavirus (HPV): Results of a Moroccan study. *Maroc Médical.* 2002, **24**: 206-211
- Arias-Pulido, H., Joste, N., Chavez, A., Muller, C.Y., Dai, D., Smith, H.O. and Verschraegen, C.F.. Absence of epidermal growth factor receptor mutations in cervical cancer. *Int J Gynecol Cancer.* 2007, **18** (4): 749-754. Oct 19.
- Arteaga, C. Targeting HER1/EGFR: a molecular approach to cancer therapy. *Semin Oncol.* 2003, **30** (Suppl. 7): 3–14.
- Barber, T.D., Vogelstein, B., Kinzler, K.W. and Velculescu, V.E. Somatic mutations of EGFR in colorectal cancers and glioblastomas. *N Engl J Med.* 2004, **351**(27): 2883.
- Baselga, J. The EGFR as a target for anticancer therapy-focus on cetuximab. *Eur J Cancer* 2001, **37** (Suppl 4): S16–S22.
- Bauer HM, Ting Y, Greer CE, Chambers JC, Tashiro JC, Chimera CL, Bauer, H.M., Ting, Y., Greer, C.E., Chambers, J.C., Tashiro, C.J., Chimera, J., Reingold, A. and Manos, M.M. Genital human papillomavirus infection in female university students as determined by a PCR-based method. *JAMA.* 1991, **256**: 472/-477.
- Bellone, S., Palmieri, M., Gokden, M., Joshua, J., Roman, J.J., Pecorelli, S., Cannon, M.J. and Santin, A.D. Selection of HER-2/neu-positive tumor cells in early stage cervical cancer: implications for Herceptin-mediated therapy. *Gynecol Oncol.* 2003, **91**(1): 231-40.
- Boiko, I, Mitchell, M, Hu, W, Pandey, D.K, Mathevet, P., Malpica, A. and Hittelman, W.N. Epidermal growth factor receptor expression in cervical intraepithelial neoplasia and its modulation during an alpha-difluoromethylornithine chemoprevention trial. *Clin. Cancer Res.* 1998, **4**(6): 1383-1391.
- Bosch, F.X., Lorincz, A., Munoz, N., Meijer, C.J. and Shah, K.V. The causal relation between human papillomavirus and cervical cancer. *J Clin Pathol.* 2002, **55**(4): 244-65.
- Bosch, F.X., Manos, M.M., Muñoz, N., Sherman, M., Jansen, A.M., Peto, J., Schiffman, M.H., Moreno, V., Kurman, R. and Shah, K.V. 1995. Prevalence of human papillomavirus in cervical cancer: a worldwide perspective. International biological study on cervical cancer (IBSCC) Study Group. *J Natl Cancer Inst.* 1995, **87**: 796–802.
- Carico, E., Atlante, M., Bucci, B., Nofroni, I. and Vecchione, A. E-cadherin and a-catenin expression during tumor progression of cervical carcinoma. *Gynecol. Oncol.* 2001, **80**: 156-161.
- Chang, J., Tsao, Y., Liu, D., Han, C., Lee, W. and Chen S. The expression of type I growth factor receptors in the squamous neoplastic changes of uterine cervix. *Gynecol Oncol.* 1999, **73**(1): 62-71.
- Chaouki, N., Bosch, F.X., Munoz, N., Meijer, C.J., El Gueddari, B., El Ghazi, A., Deacon, J., Castellsagué, X. and Walboomers, J.M. The viral origin of cervical cancer in Rabat, Morocco. *Int. J. Cancer* 1998, **75**(4): 546-554.
- Chapman, W.B., Lorincz, A.T., Willett, G.D., Wright, V.C. and Kurman, R.J.. Epidermal growth factor receptor expression and the presence of human papillomavirus in cervical squamous intraepithelial lesions. *Int J Gynecol Pathol* 1992, **11**(3): 221-226.
- Chen, C.L., Liu, S.S., Ipb, S.M., Wongb, L.C., Ng, T.Y. and Nganb, H.Y.S. E-cadherin expression is silenced by DNA methylation in cervical cancer cell lines and tumours. *Eur. J. Cancer.* 2003, **39**: 517-523. 2003.
- Chichareon, S., Herrero, R., Muñoz, N., Bosch, F.X., Jacobs, M.V., Deacon, J., Santamaria, M., Chongsuvivatwong, V., Meijer, C.J. and Walboomers, J.M.

- Risk factors for cervical cancer in Thailand: a case-control study. *J Natl Cancer Inst.* 1998, **90**(1): 50-7.
20. Ciardiello, F. and Tortora, G. EGFR antagonists in cancer treatment. *The New England Journal of Medicine.* 2008, **358**: 1160–1174.
21. Ciardiello, F and Tortora G. Epidermal growth factor receptor (EGFR) as a target in cancer therapy: understanding the role of receptor expression and other molecular determinants that could influence the response to anti-EGFR drugs. *Eur J Cancer* 2003, **39**: 1348-54.
22. de Boer, C.J., van Dorst, E., van Krieken, H., Jansen-van Rhijn, C.M., Warnaar, S.O., Fleuren, G.J. and Litvinov, S.V. Changing roles of cadherins and catenins during progression of squamous intraepithelial lesions in the uterine cervix. *Am. J. Pathol.* 1999, **155**: 505–515.
23. Dellas, A., Schultheiss, E., Almendral, A.C., Torhorst, J. and Gudat, F. Assessment of EGFR and TGF- α expression in relationship to HPV status and Ki-67 distribution in cervical intraepithelial neoplasms. *Int J Cancer.* 1996, **69**(3):165-169.
24. Derksen, P.W., Liu, X., Saridin, F., van der Gulden, H., Zevenhoven, J., Evers, B., van Beijnum, J.R., Griffioen, A.W., Vink, J., Krimpenfort, P., Peterse, J.L., Cardiff, R.D., Berns, A. and Jonkers, J. Somatic inactivation of E-cadherin and p53 in mice leads to metastatic lobular mammary carcinoma through induction of anoikis resistance and angiogenesis. *Cancer Cell.* 2006, **10**: 437–449.
25. Eluf-Neto, J., Booth, M., Munoz, N., Bosch, F.X., Meijer, C.J.L.M. and Walboomers, J.M.M., Human papillomavirus and invasive cervical cancer in Brazil. *Brit. J. Cancer.*, 1994, **69**: 114-119. (1994).
26. Frappart, L., Fontanie`re, B., Lucas, E. and Sankaranarayanan, R. 2004. Histopathology of the uterine cervix. In Histopathology and cytopathology of the Uterine Cervix – Digital Atlas. 2004, IARC Cancer base N° 8.
27. Gaffney, D.K., Haslam, D., Tsodikov, A., Hammond, E., Seaman, J., Holden, J., Lee, R.J., Zempolich, K. and Dodson, M. Epidermal growth factor receptor (EGFR) and vascular endothelial growth factor (VEGF) negatively affect overall survival in carcinoma of the cervix treated with radiotherapy. *Int J Radiat Oncol Biol Phys.* 2003, **56**(4): 922-928.
28. Galizia, G., Lieto, E., De Vita, F., Orditura, M., Castellano, P., Troiani, T., Imperatore, V. and Ciardiello, F. Cetuximab, a chimeric human mouse anti-epidermal growth factor receptor monoclonal antibody, in the treatment of human colorectal cancer. *Oncogene* 2007, **26**: 3654-3660.
29. Ghaffari, S.R., Sabokbar, T., Mollahajian, H., Dastan, J., Ramezanzadeh, F., Ensani, F., Yarandi, F., Mousavi-Jarrahi, A., Mohagheghi, M.A. and Moradi, A. 2006. Prevalence of human papillomavirus genotypes in women with normal and abnormal cervical cytology in Iran. *Asian Pac J Cancer Prev.* 2006, **7**(4): 529-532.
30. Gonzalgo, M.L., Hayashida, T., Bender, C.M., Pao, M.M., Tsai, Y.C., Gonzales, F.A., Nguyen, H.D., Nguyen, T.T. and Jones, P.A. The role of DNA methylation in expression of the p19/p16 locus in human bladder cancer cell lines. *Cancer Res.* 1998, **58**: 1245-1252.
31. Gould Rothberg, B.E. and Bracken, M.B. E-cadherin immunohistochemical expression as a prognostic factor in infiltrating ductal carcinoma of the breast: a systematic review and meta-analysis. *Breast Cancer Res. Treat.* 2006, **100**: 139–148.
32. Gridelli, C., Bareschino, M.A., Schettino, C., Rossi, A., Maione, P. and Ciardiello, F. Erlotinib in non-small cell lung cancer treatment: current status and future development. *Oncologist.* 2007, **12**: 840-849.
33. Herrero, R., Castle, P.E., Schiffman, M., Bratti, M.C., Hildesheim, A., Morales, J., Alfaro, M., Sherman, M.E., Wacholder, S., Chen, S., Rodriguez, A.C. and Burk, R.D. 2005. Epidemiologic profile of type-specific human papillomavirus infection and cervical neoplasia in Guanacaste, Costa Rica. *J Infect Dis.* 2005, **191**(11): 1796-1807.
34. Hirohashi, S. Inactivation of the E-cadherin-mediated cell adhesion system in human cancers. *Am. J. Pathol.* 1998, **153**: 333–339.
35. Hu, G., Liu, W., Mendelsohn, J., Ellis, L.M., Radinsky, R. Andreeff, M. and Deisseroth, A.B. Expression of epidermal growth factor receptor and human papillomavirus E6/E7 proteins in cervical carcinoma cells. *J. Natl. Cancer Inst.* 1997, **89**(17): 1271-1276.
36. Ivanova, T.A., Golovina, D.A., Zavalishina, L.E., Volgareva, G.M., Katargin, A. N., Andreeva, Y.Y., Frank, G.A., Kisseljov, F.L. and Kisseljova, N.P. Up-regulation of expression and lack of 5' CpG island hypermethylation of p16 INK4a in HPV-positive cervical carcinomas. *BMC Cancer.* 2007, **7**: 47-56.
37. Karamouzis, M.V., Grandis, J.R. and Argiris, A. Therapies directed against epidermal growth factor receptor in aerodigestive carcinomas. *JAMA* . 2007, **298**: 70-82.
38. Kay, P., Soeters, R., Nevin, J., Denny, L., Dehaeck, C.M.C. and Williamson, A.L. 2003. High prevalence of HPV 16 in South African women with cancer of the cervix and cervical intraepithelial neoplasia. *J Med Virol.* 2003, **71**: 265-273.
39. Kedzia, W., Schmidt, M., Frankowski, A., Spaczynski, M. Immunohistochemical assay of p53, cyclin D1, c-erbB2, EGFR and Ki-67 proteins in HPV-positive and HPV-negative cervical cancers. *Folia Histochem Cytobiol.* 2002, **40**(1): 37-41.
40. Kim, G.E., Kim, Y.B., Cho, N.H., Chung, H.C., Pyo, H.R., Lee, J.D., Park, T.K., Koom, W.S., Chun, M. and Suh, C.O. Synchronous Coexpression of Epidermal Growth Factor Receptor and Cyclooxygenase-2 in Carcinomas of the Uterine Cervix: A Potential Predictor of Poor Survival. *Clin Cancer Res.* 2004, **10**(4): 1366-1374.
41. Klaes, R., Friedrich, T., Spitkovsky, D., Ridder, R., Rudy, W., Petry, U., Dallenbach-Hellweg, G., Schmidt, D. and von Knebel Doeberitz, M. Overexpression of p16(INK4A) as a specific marker for dysplastic and neoplastic epithelial cells of the cervix uteri. *Int J Cancer.* 2001, **92**: 276–284.
42. Lee, C.M., Lee, R.J., Hammond, E., Tsodikov, A., Dodson, M., Zempolich, K. and Gaffney, D.K. Expression of HER2neu (c-erbB-2) and epidermal growth factor receptor in cervical cancer: prognostic correlation with clinical characteristics, and comparison of manual and automated imaging analysis. *Gynecol Oncol.* 2004, **93**(1): 209-14.
43. Lee C.M., Shrieve, D.C., Zempolich, K.A., Lee, R.J., Hammond, E., Handrahan, D.L. and Gaffney, D.K. Correlation between human epidermal growth factor receptor family (EGFR, HER2, HER3, HER4), phosphorylated Akt (P-Akt), and clinical outcomes after radiation therapy in carcinoma of the cervix. *Gynecol Oncol.* 2005, **99**(2): 415-421.
44. Leung, T.W., Cheung, A.N., Cheng, D.K., Wong, L.C. and Ngan, H.Y. Expressions of c-erbB-2, epidermal growth factor receptor and pan-ras proto-oncogenes in adenocarcinoma of the cervix: correlation with clinical prognosis. *Oncol Rep.* 2001, **8**(5): 1159-1164.
45. Liu, X., Clements, A. and Zhao, K. Structure of the human papillomavirus E7 oncoprotein and its mechanism

- for inactivation of retinoblastoma tumor suppressor. *J. B. C.* 2006, **281**: 578-586.
46. Marchetti, A., Martella, C., Felicioni, L., Barassi, F., Salvatore, S., Chella, A., Campese, P.P., Iarussi, T., Mucilli, F., Mezzetti, A., Cuccurullo, F., Sacco, R. and Buttitta, F. EGFR Mutations in Non-Small-Cell Lung Cancer: Analysis of a Large Series of Cases and Development of a Rapid and Sensitive Method for Diagnostic Screening With Potential Implications on Pharmacologic Treatment. *J Clin Oncol.* 2005, **23**(4): 857-865.
47. Mareel, M., Berx, G., van Roy, F. and Bracke, M.: Cadherin/catenin complex: a target for antiinvasive therapy.? *J. Cell Biochem.* 1996, **61**: 524-530.
48. Marzano, R., Corrado, G., Merola, R., Sbiroli, C., Guadagni, F., Vizza, E., Del Nonno, F., Carosi, M., Galati, M.M., Sperduti, I. and Cianciulli, A.M. Analysis of chromosomes 3, 7, X and the EGFR gene in uterine cervical cancer progression. *Eur J Cancer.* 2004, **40**(10): 1624-1629.
49. Mathur, S.P., Mathur, R.S., Rust, P.F. and Young, R.C. Human papilloma virus (HPV)-E6/E7 and epidermal growth factor receptor (EGF-R) protein levels in cervical cancer and cervical intraepithelial neoplasia (CIN). *Am J Reprod Immunol.* 2001, **46**(4): 280-287.
50. Meftah El Khair, M., M. El Mzibri, M., R. Ait Mhand, R., A. Benider, A., N. Benchekroun, N., M. El fahime, M., M.N. Benchekroun, M.N. and M.M. Ennaji, M.M. 2009. Molecular detection and genotyping of human papillomavirus in cervical carcinoma biopsies in an area of high incidence of cancer from Moroccan women. *J. Med Virol.* 2009, **81**: 678-684.
51. Mendelsohn, J. and Baselga, J. Status of epidermal growth factor receptor antagonists in the biology and treatment of cancer. *J Clin Oncol.* 2003, **21**: 2787-99.
52. Messersmith, W.A. and Hidalgo, M. Panitumumab, a monoclonal anti epidermal growth factor receptor antibody in colorectal cancer: another one or the one? *Clin Cancer Res.* 2007, **13**: 4664-4666.
53. Milde-Langosch, K., Riethdorf, S., Kraus-Poppinghaus, A., Riethdorf, L. and Loning, T. Expression of cyclin-dependent kinase inhibitors p16MTS1, p21WAF1, and p27KIP1 in HPV-positive and HPV-negative cervical adenocarcinomas. *Virchows Arch.* 2001, **439**: 55-61.
54. Nagai, N., Oshita, T., Fujii, T., Kioka, H., Katsube, Y. and Ohama, K. Prospective analysis of DNA ploidy, proliferative index and epidermal growth factor receptor as prognostic factors for pretreated uterine cancer. *Oncol Rep.* 2000, **7**(3): 551-559.
55. Ngan, H.Y., Cheung, A.N., Liu, S.S., Cheng, D.K., Ng, T.Y. and Wong, L.C. Abnormal expression of epidermal growth factor receptor and c-erbB2 in squamous cell carcinoma of the cervix: correlation with human papillomavirus and prognosis. *Tumour Biol.* 2001, **22**(3): 176-183.
56. Ngelangel, C., Muñoz, N., Bosch, F.X., Limson, G.M., Festin, M.R., Deacon, J., Jacobs, M.V., Santamaria, M., Meijer, C.J., Walboomers, J.M.. Causes of cervical cancer in the Philippines: a case-control study. *J Natl Cancer Inst.* 1998, **90**(1): 43-49.
57. Nicholson RI, Gee JM, Harper ME. EGFR and cancer prognosis. *Eur J Cancer.* 2001, **37**(suppl.4):S9-15.
58. Normanno, N., Bianco, C., De Luca, A., Maiello, M.R. and Salomon, D.S. Target-based agents against ErbB receptors and their ligands: a novel approach to cancer treatment. *Endocr Relat Cancer.* 2003, **10**: 1-21.
59. Paez, J.G., Janne, P.A., Lee, J.C. Tracy, S., Greulich, H., Gabriel, S., Herman, P., Kaye, F.J., Lindeman, N., Boggon, T.J., Naoki, K., Sasaki, H., Fujii, Y., Eck, M.J., Sellers, W.R., Johnson, B.E. and Meyerson, M. EGFR mutations in lung cancer: correlation with clinical response to gefitinib therapy. *Science.* 2004, **304**: 1497-1500.
60. Pao, W., Miller, V., Zakowski, M. Doherty, J., Politi, K., Sarkaria, I., Singh, B., Heelan, R., Rusch, V., Fulton, L., Mardis, E., Kupfer, D., Wilson, R., Kris, M. and Varmus, H. EGF receptor gene mutations are common in lung cancers from "never smokers" and are associated with sensitivity of tumors to gefitinib and erlotinib. *Proc Natl Acad Sci USA.* 2004, **101**: 13306-13311.
61. Parkin, D., Pisani, P. and Ferlay, J. Estimates of the worldwide incidence of 25 major cancers in 1990. *Int J Cancer.* 1999, **80**(6): 827-841.
62. Riethdorf, S., Neffen, E.F., Cviko, A., Loning, T., Crum, C.P. and Riethdorf, L. P16^{INK4A} expression as biomarker for HPV 16-related vulvar neoplasias. *Hum Pathol.* 2004, **35**: 1477 - 1483.
63. Rolon, P.A., Smith, J.S., Munoz, N., Klug, S.J., Herrero, R., Bosch, X., Llamasos, F., Meijer, C.J. and Walboomers, J.M. Human papillomavirus infection and invasive cervical cancer in Paraguay. *Int J Cancer.* 2000, **85**: 486-491
64. Salomon, D.S., Brandt, R., Ciardiello, F. and Normanno, N. Epidermal growth factor related peptides and their receptor in human malignancies. *Critical Rev Oncol Hematol.* 1995, **19**: 183-232.
65. Sambrook, J., Fritsch, E.F. and Maniatis, T. Molecular Cloning: A laboratory manual. Cold Spring Harbor Laboratory Press 1989, Cold Spring Harbor.
66. Santos, C., Munoz, N., Klug, S., Almonte, M., Guerrero, I., Alvarez, M., Velarde, C., Galdos, O., Castillo, M., Walboomers, J., Meijer, C. and Caceres, E. HPV types and cofactors causing cervical cancer in Peru. *Br J Cancer.* 2001, **85**: 966-71.
67. Sharma SV, Bell DW, Settleman J, Haber DA. Epidermal growth factor receptor mutations in lung cancer. *Nat Rev Cancer.* 2007, **7**: 169-181.
68. Sizemore, N., Choo, C.K., Eckert, R.L. and Rorke, E.A. Transcriptional regulation of the EGF receptor promoter by HPV16 and retinoic acid in human ectocervical epithelial cells. *Exp Cell Res.* 1998, **244**(1): 349-56.
69. Stoler, M.H. and Schiffman, M. Interobserver reproducibility of cervical cytologic and histologic interpretations: realistic estimates from the ASCUS-LSIL Triage Study. *JAMA.* 2001, **285**: 1500-1505.
70. Straight, S. W., Herman, B. and McCance, D. J. The E5 oncoprotein of human papillomavirus type 16 inhibits the acidification of endosomes in human keratinocytes. *J. Virol.* 1995, **69**: 3185-3192.
71. Straight, S.W., Hinkle, P.M., Jewers, R.J. and McCance, D.J. The E5 oncoprotein of human papillomavirus type 16 transforms fibroblasts and effects the downregulation of the epidermal growth factor receptor in keratinocytes. *J. Virol.* 1993, **67**(8): 4521-4532.
72. Trottier, H., Mahmud, S., Costa, M.C., Sobrinho, J.P., Franco, E.D., Rohan, T.E., Ferenczy, A., Villa, L.L. and Franco, E.L. 2006. Human Papillomavirus Infections with Multiple Types and Risk of Cervical Neoplasia. *Cancer Epidemiol Biomarkers Prev.* 2006, **15**: 1274-1279.
73. Uramoto, H., Sugio, K., Oyama, T., Ono, K., Sugaya, M., Yoshimatsu, T., Hanagiri, T., Morita, M. and Yasumoto, K. (2006). Epidermal growth factor receptor mutations are associated with gefitinib sensitivity in non-small cell lung cancer in Japanese. *Lung Cancer.* 2006, **51**, 71-77.
74. Wentzensen, N., Bergeron, C., Cas, F., Vinokurova, S. and von Knebel Doeberitz, M. Triage of women with ASCUS and LSIL cytology: use of qualitative assessment of

- p16^{INK4a} positive cells to identify patients with high-grade cervical intraepithelial neoplasia. *Cancer*. 2007, **111**: 58-66.
75. Wright, T.C., Denny, L., Kuhn, L., Pollack, A. and Lorincz, A. HPV DNA testing of self-collected vaginal samples compared with cytologic screening to detect cervical cancer. *JAMA*. 2000, **283**: 81-86.
76. Zhang, B., Srirangam, A., Potter, D.A., Roman, A. HPV 16 E5 protein human foreskin keratinocytes. *Oncogene*. 2005, **24**: 2585-2588.
77. Zhu, X., Rottkamp, C.A., Hartzler, A., Sun, Z., Takeda, A., Boux, H., Shimohama, S., Perry, G. and Smith, M.A. Activation of MKK6, an upstream activator of p38, in Alzheimer's disease. *J. Neurochem*. 2001, **79**: 311-318.