



**HAL**  
open science

## Heterogeneous clinical features in Cockayne syndrome-A patients with the same mutation and in siblings

Asma Chikhaoui, Ichraf Kraoua, Nadège Calmels, Sami Bouchoucha, Cathy Obringer, Khoulood Zayoud, Benjamin Montagne, Ridha M'Rad, Sonia Abdelhak, Vincent Laugel, et al.

### ► To cite this version:

Asma Chikhaoui, Ichraf Kraoua, Nadège Calmels, Sami Bouchoucha, Cathy Obringer, et al.. Heterogeneous clinical features in Cockayne syndrome-A patients with the same mutation and in siblings. 2022. pasteur-03548783

**HAL Id: pasteur-03548783**

**<https://riip.hal.science/pasteur-03548783>**

Preprint submitted on 31 Jan 2022

**HAL** is a multi-disciplinary open access archive for the deposit and dissemination of scientific research documents, whether they are published or not. The documents may come from teaching and research institutions in France or abroad, or from public or private research centers.

L'archive ouverte pluridisciplinaire **HAL**, est destinée au dépôt et à la diffusion de documents scientifiques de niveau recherche, publiés ou non, émanant des établissements d'enseignement et de recherche français ou étrangers, des laboratoires publics ou privés.



Distributed under a Creative Commons Attribution 4.0 International License

# Heterogeneous clinical features in Cockayne syndrome-A patients with the same mutation and in siblings

**Asma CHIKHAOUI**

Institut Pasteur de Tunis

**Ichraf Kraoua**

Institut National de Neurologie Mongi-Ben Hamida

**Nadège Calmels**

Universite de Strasbourg Faculte de Medecine

**Sami Bouchoucha**

Hopital d'Enfant Bechir Hamza

**Cathy Obringer**

Hopitaux universitaires de Strasbourg

**Khoulood Zayoud**

Institut Pasteur de Tunis

**Benjamin Montagne**

UMR3738: Bases genetiques moleculaires et cellulaires du developpement

**Ridha M'rad**

Hopital Charles Nicolle

**Sonia Abdelhak**

Institut Pasteur de Tunis

**Vincent Laugel**

Hopitaux universitaires de Strasbourg

**Miria Ricchetti**

UMR3738: Bases genetiques moleculaires et cellulaires du developpement

**Ilhem Turki**

Institut National de Neurologie Mongi-Ben Hamida

**Houda Yacoub-Youssef** (✉ [houda.yacoub@pasteur.utm.tn](mailto:houda.yacoub@pasteur.utm.tn))

Institut Pasteur de Tunis <https://orcid.org/0000-0001-5351-4775>

---

## Research

**Keywords:** Cockayne syndrome, targeted gene sequencing, ERCC8, CSA, clinical heterogeneity, siblings

**Posted Date:** June 15th, 2021

**DOI:** <https://doi.org/10.21203/rs.3.rs-603999/v1>

**License:**  This work is licensed under a Creative Commons Attribution 4.0 International License. [Read Full License](#)

---

## Abstract

## Background

Cockayne syndrome (CS) is a rare autosomal recessive disorder caused by mutations in *ERCC6/CSB* or *ERCC8/CSA* that participate in transcription-coupled nucleotide excision repair (TC-NER) of UV-induced DNA damage. CS patients display a large heterogeneity of clinical symptoms and severities, the reason of which is not fully understood, and little data is available for affected siblings. CS is largely undiagnosed in North Africa.

## Methods

We report here the clinical description as well as genetic and functional characterization of eight North African CS patients, including siblings. These patients, who belonged to six unrelated families, underwent complete clinical examination and biochemical analyses. Sanger sequencing was performed for the recurrent mutation in five families, and targeted gene sequencing for one patient of the other family. We also performed RRS (Recovery RNA Synthesis) to confirm the functional impairment of DNA repair in the identified mutations.

## Results

Six out of eight patients carried a homozygous indel mutation (c.598\_600delinsAA) in exon 7 of *ERCC8*, and displayed a variable clinical spectrum, including between siblings, despite sharing the same mutation. The other two patients were Tunisian siblings who carried a homozygous splice-site variant in *ERCC8* (c.843 + 1 G > C). They presented more severe clinical manifestations, which are in general rarely associated with CSA mutations, leading to gastrostomy and hepatic damage. Impaired TC-NER was confirmed by RRS in six tested patients.

## Conclusions

This study provides the first deep characterization of case series of rare CS-A patients in North Africa. They carry mutations described to date only in this region and the Middle-East. We also provide the largest characterization of unrelated patients, as well as siblings, with the same mutation, providing a framework for dissecting elusive genotype-phenotype correlations in CS.

## Background

Nucleotide excision repair (NER) is a complex DNA repair system capable of removing a variety of DNA lesions such as UV-induced photolesions and chemical adducts (1). In humans, it operates through two major pathways: Transcription-Coupled NER (TC-NER) that repairs DNA damage on the transcribed DNA strand, and Global-Genome NER (GG-NER) that is less specific and ensures repair of the entire genome, including non-transcribed regions and silent chromatin (2).

Deficiencies in one of the proteins implicated in NER result in heterogeneous rare disorders such as Xeroderma pigmentosum (XP), Trichothiodystrophy (TTD), and Cockayne syndrome (CS) (3). Some of these diseases are frequently associated with neurodegeneration (TTD, CS), and others with cancer predisposition (XP, but not CS). CS patients display accelerated ageing, and the disease is defined as a segmental progeroid syndrome (*i.e.* that displays some features associated with ageing). CS is characterized by growth failure, progressive neurologic dysfunction, microcephaly, and intellectual disability along with other defects such as cutaneous photosensitivity, kyphosis, ankylosis, and optic atrophy (4). The phenotype of CS patients varies widely, and phenotype-genotype correlation remains elusive (5). The phenotypic variability of CS patients is challenging also for establishing a diagnosis and supportive treatments, since patients with the most severe forms exhibit a very short life expectancy (8.4 years) (6), and to date no cure is available.

In Europe, the incidence of this syndrome is estimated to less than 2.7 per million (7). Although the incidence rates of other DNA repair disorders such XP have been reported in Tunisia (8), no epidemiological data are available in the rest of North Africa, and they are missing for CS throughout the region.

To date, genetic investigations have identified two genes associated with Cockayne syndrome: *ERCC8* that codes for the CSA protein, and *ERCC6* that codes for the CSB protein. Furthermore, an extremely rare combined form of XP/CS has been associated with *XPG* mutations. CSA forms a complex with the DDB1-CUL4-based E3 ubiquitin ligase complex (9) (10) that is activated in response to UV irradiation and is essential for the recruitment of the TC-NER protein machinery. CSB plays multiple roles: in addition to initiate TC-NER, CSB has ATPase-dependent chromatin remodeling activity, is involved in another type of DNA repair (base excision repair, or BER), and is implicated in transcription regulation (11).

In Tunisia and North Africa, genetic diagnosis of CS is not performed due to the absence of referral centers. Nevertheless, a few studies reported fragmented and incomplete clinical aspects, which were not sufficient to allow clinicians to identify the disease and ensure early diagnosis.

Here, we report an extensive clinical description and conduct genetic and functional investigations of eight CS patients to define CS-A forms of the disorder in the Tunisian population. This study represents the largest cohort reported in the region, and also describes two cases of siblings as well as multiple patients carrying the same mutation, which is relevant for global investigation of genotype/phenotype correlations in CS.

## Results

### General presentation of the patients

Clinical, imaging, and genetic characterization of the eight patients are summarized in Table 1. This cohort includes 6 males and 2 females from six unrelated Tunisian families (CS1, CS2, CS6, CS7, CS11 and CS16). Consanguinity, examined by genealogical data, was found in 4 families (CS2, CS6, CS11, and CS16) and endogamy was reported for two other families (CS1 and CS7). All patients originated from the North West of Tunisia except CS2 that originated from South Tunisia. The mean age of patients at the time of examination was 3.4 years ranging from 1.5 year to 7 years. At the time of the study, all patients were alive (Fig. 1).

Table 1  
Clinical, biological, imaging and genetic findings of CS patients

Family	CS1		CS2	CS6		CS7	CS11	CS17
Patients	EA1	EA2	EA	EA1	EA2	EA	EA	EA
Sex	F	M	M	M	M	M	M	F
Homozygous ERCC8 mutation	c.843 + 1G > C		c.598_600delinsAA	c.598_600delinsAA		c.598_600delinsAA	c.598_600delinsAA	c.598_600delinsAA
Geographic origin	North west		South	North west		North west	North west	North west
Consanguinity/Endogamy	Endogamous		Consanguineous	Consanguineous		Endogamous	Consanguineous	Consanguineous
Age at diagnosis (years. months)	5	1.6	4	3	1.5	4	1.8	7
Age at first symptoms (months)	12	12	6	24	17	12	Birth	5
Gastrostomy	+	-	-	-	-	-	-	-
First symptoms	PMD, GD, microcephaly		GD	PMD	PMD	PMD	Arthrogryposis	PMD
Prenatal abnormalities	+	+	-	-	-	-	+	+
- IUGR	-	+	-	-	-	-	-	-
- Microcephaly	-	-	-	-	-	-	-	-
- Cerebellar hypoplasia	-	+	-	-	-	-	-	-
- Oligoamnios	-	-	-	-	-	-	-	-
Birth findings	2300	2550	2450	3300	3400	2650	2500	1450
- Birth weight (g)	49	45,5	48	51	50	49	44	39
- Birth height (cm)	34	32.5	32.5	35	34	34	31	28
-Head circumference at birth (cm)	-	-	-	-	-	-	-	-
Postnatally findings (years.months)	3.4	1.3	3.7	4.6	2	4	1.8	7.5
-Weight (kg)	12 (-3SD)	7	10 (-4SD)	14 (-2SD)	11 (-2SD)	10 (-4SD)	6,8 (-4SD)	9 (-4SD)
-Height (cm)	95(normal)	NA	68 (-6SD)	98 (normal)	83 (-1SD)	89 (-3SD)	71 (normal)	82 (normal)
-Head circumference (cm)	43(-4SD)	40 (-4SD)	43 (-5SD)	47 (-3SD)	46 (-2SD)	45 (-4SD)	41 (-3SD)	38 (-4SD)
Dysmorphism	+	+	+	+	+	+	+	+
- Enophthalmia	+	+	+	+	+	+	+	+
- Thin skin	+	-	+	-	-	+	+	+
- Bird like nose	-	-	-	-	-	-	-	-

\* AST / ALT: tested twice (1 and 3 years old) the value normalized at the age of 3 years (47/53).

NA: Not available NL: Normal

SD: Standard Deviation

GD: growth delay

PMD: Psychomotor Disturbance

Family	CS1		CS2		CS6		CS7		CS11		CS'
Neurological findings	+	+	+	+	+	+	+	+	+	+	+
- Microcephaly	+	+	+	+	+	+	+	+	+	+	+
- Psychomotor delay	+(18)	NA	+(18)	+(9)	+(8)	+(20)	-	-	-	-	-
	+(2.5)	NA	-	+(2)	-	+(3)	-	-	-	-	-
*Independent Sitting (months)	+	+	+	+	+	+	+	+	+	+	+
*Independent walking (years)	+	-	+	+	+	+	+	+	+	+	+
- Mental retardation	+	+	+	+	+	+	+	+	+	+	+
- Limb spasticity	-	-	-	-	-	-	-	-	+	-	-
- Retractions	+	-	-	-	-	-	+	+	+	-	-
- Pyramidal signs	-	-	-	-	-	-	-	-	-	-	-
- Neurogenic signs	+(irritability)	-	-	-	-	-	-	-	-	-	-
- Ataxia											
- Extrapyramidal signs											
- Epilepsy											
- Behavioural abnormalities											
Ophthalmological findings	-	+	-	-	-	+	+	+	+	+	+
-Cataracts	-	-	-	-	-	-	-	-	-	-	-
-Optic atrophy	-	-	+	-	-	-	-	-	-	-	-
-Pigmentary retinopathy											
Otolaryngological findings	+	+	+	+	+	+	+	+	+	+	+
-Sensorineural deafness	90 dB	50/60 Db	50dB	90/100dB	NA	70dB	NA	NA	NA	NA	NA
- Auditory evoked response											

\* AST / ALT: tested twice (1 and 3 years old) the value normalized at the age of 3 years (47/53).

NA: Not available NL: Normal

SD: Standard Deviation

GD: growth delay

PMD: Psychomotor Disturbance

Family	CS1		CS2	CS6		CS7	CS11		CS16
Dermatological findings	-	-	+	+	+	+	-	+	+
-Photosensitivity	-	-	-	-	-	-	-	-	-
-Eczema	+	+	+	+	+	+	+	+	+
-Thin skin	+	+	-	+	+	-	-	-	-
-Pigmentation abnormalities	+	-	-	-	-	-	-	-	-
-Hair abnormalities	-	-	-	-	-	-	-	-	-
-Nail abnormalities	-	-	-	-	-	-	-	-	-
Dental abnormalities	+	-	-	+	-	+	-	+	+
-Caries	+	-	-	+	-	-	-	-	-
-Tooth enamel abnormalities	+	-	-	+	-	-	-	-	+
-Morphological tooth abnormalities	-	-	-	-	-	-	-	-	-
Laboratory findings	964*	56	62	40	41	41	37	30	30
-AST (NV <40 U/l)	1780*	48	91	60	46	47	32	32	32
-ALT (NV < 40 U/l)	0.75 g/l	NA	NA	NA	NA	NA	NA	NA	NA
-CSF protein level (NV < 0.4gr/l)	-	-	-	-	-	-	-	-	-
Imaging findings	+	+	+	+	+	+	+	+	NA
-Calcifications	-	-	+	-	NA	+	+	+	+
-Hypomyelination	+	-	+	-	NA	+	-	-	+
-Cerebellar atrophy	-	-	-	-	NA	-	-	-	+
-Brainstem atrophy	-	-	-	-	-	-	-	-	-
<b>Nerve conduction velocities</b>	NL (45 m/s)	NL (45 m/s)	Slightly slowed 36 m/s	NL (45 m/s)	NA	Slowed 23–35 m/s	Slowed 13–32 m/s	Slowed 13–32 m/s	Slowed 13–32 m/s
<b>Others Findings</b>	Cryptorchidism		Cryptorchidism						
* AST / ALT: tested twice (1 and 3 years old) the value normalized at the age of 3 years (47/53).									
NA: Not available NL: Normal									
SD: Standard Deviation									
GD: growth delay									
PMD: Psychomotor Disturbance									

## Post- and pre-natal abnormalities

Intra-uterine growth retardation (IUGR) was noted in four patients (CS1EA1, CS1EA2, CS11, CS16). No prenatal malformation was detected in ultrasound screening for 7 out of the eight CS patients, except for CS1EA2 who displayed microcephaly (Table 1). Delivery was at full term for all patients except CS16

born in the eighth month of pregnancy. No perinatal asphyxia was reported. Birth weight was within the low normal range for all patients (mean birth weight: 2575 g, ranging from 1450 g (as for CS16) to 3400 g). Based on the head circumference at birth, all patients except CS16 (N = 7) were normocephalic (mean birth head circumference: 33.28 cm). Postnatally, all patients developed progressive growth failure and microcephaly (mean head circumference – 3SD: standard deviation defined according to growth curve) (Table 1), (Supplementary Fig. 1).

## Behavioral abnormalities, muscular neurological and neurosensory problems

All patients arrived in our department for examination displayed psychomotor delay. Five patients were able to sit independently at a mean age of 13 months whereas two patients (CS11 and CS 16) were incapable to do so. Walking without support was acquired in two cases (CS6EA1 et CS7) at 2 and 3 years, respectively, and then lost as the syndrome progressed (mainly due to contractures). Another patient (CS1EA1) was capable of walking with support at 30 months without reported abnormalities. The five other patients were unable to walk alone.

As a general observation, none of the patients had language skills at the time of examination. However, they were outgoing and interactive. Behavioral disturbance with irritability and sleep disorder were not reported except for patient CS1EA1. Neurological examination showed a spasticity of limbs with predominance in lower limbs in all patients leading to a progressive flexion retraction in 6 patients, associated with ataxia and tremor in three cases (CS1EA1, CS7, CS11), and neurological signs in one case (CS11, age 4). No patient had extrapyramidal signs. Kyphosis was noted in two patients (CS16 and CS1EA2). In three patients the severity of retractions needed surgical intervention (CS1EA2, CS11, and CS16). Sensorineural deafness was detected in seven cases (all patients except CS11). Ophthalmological examination performed in 5 patients showed bilateral cataracts in four patients (CS1EA2, CS7, CS11, and CS16), and pigmentary retinopathy in one case (CS2).

## Facial, dental, and skin anomalies

All patients had characteristic facial appearance of CS with enophthalmia, large ears, and thin skin. Bird-like nose was noted in five patients (all patients except CS1EA2, and both CS6 patients). This facial phenotype was generally more evident in older patients (5–7 years old). Dental caries were observed in four cases (CS1EA1, CS6EA1, CS7, and CS16). Anomalies in tooth shape, size and number were reported in three patients (CS1EA1, CS6EA1, CS16). Photosensitivity was observed in five patients out of eight (not detected in CS1 and CS11 patients). Pigmentation abnormalities were observed in four patients (siblings of the CS1 and CS6 families).

## Laboratory investigations

Mild serum aminotransferase elevation (2N) was noted in all patients before the age of three except CS11 and CS16. The biochemical analysis of AST/ALT was done longitudinally for patient CS1EA1, who showed cytolysis (964/1780) at the age of one year, but these values normalized progressively at the age of 3 years (47/53) (Table 1).

CSF (Cerebrospinal Fluid) analysis was performed in the patient CS1EA1 and showed a mild increase of CSF lactate level (2.13 mmol/l; normal value < 2); this patient also displayed mild elevation of creatinine kinase (824 U/l; normal value < 145).

## Neuroimaging analysis

Computed tomography was performed for 7 patients (except CS16) and showed lenticular calcifications in all of them. Magnetic resonance imaging was performed in these 7 patients as well, showing hypomyelination in four cases (CS2, CS7, CS11, CS16) and cerebellar atrophy in other four cases (CS1EA1, CS2, CS7, CS16) (Table 1). Cerebral MRI images of CS7 illustrate the white matter anomalies (Fig. 2).

## Neurophysiological studies

Nerve conduction velocities were studied in 7 patients, and values were reduced (< 45m/s) in 4 patients (Table 1). Electroretinogram was performed once and was normal in this case.

## Genetic analysis reveals the same mutation in six patients

We first screened the eight patients by Sanger sequencing of *ERCC8* exon 7, which revealed that six (CS2, both CS6, CS7, CS11, and CS16) out of eight CS patients were homozygous carriers for the variant NM\_000082.3: c. 598\_600delinsAA p.Tyr200Lysfs\*12. This variant that introduces a stop codon and therefore a truncated protein has been previously described in several unrelated CS patients from North Africa (12, 13) (and unpublished data). We also confirmed parental segregation of the mutation in all cases (Fig. 3). The recurrent variation was absent in the affected siblings from (CS1 family).

### Genetic analysis of the CS1 family

## - Identification of an intronic variant via targeted gene sequencing

In one patient of the CS1A family, screening of 17 genes involved in NER pathway using NGS revealed a homozygous transversion in *ERCC8* gene at the position NM\_000082.3:c.843 + 1G > C (Fig. 3). This variant represents a transversion from guanine to cytosine located at the donor splice site of intron 9. This variation was reported previously in a Lebanese CS patient (14). Sanger sequencing confirmed that this mutation was homozygous in the two affected patients (siblings) from this family, and heterozygous in their parents, as expected.

## - In silico effect of the variation on splicing site

The variant modified the consensus donor splice site region in intron 9 of the gene *ERCC8*, from the conserved GT motif to CT. This mutation is expected to alter the mRNA splicing by affecting the donor site signal, according to the prediction tools Human Splicing Finder (HSF) and MaxEntScan. In particular using



HSF, the potential impact of the variation was assessed through attribution of consensus value (CV) according to the matrices from Shapiro and Senepathy (15). The difference between the wild type and the mutant had a CV of (-32. 71%), and was predicted by the program to abolish the donor site, thereby affecting the splicing process.

## - cDNA analysis of the splice site mutation

To confirm and functionally validate the mutation at the splice site, mRNA extracted from primary fibroblasts derived from the CS1EA1 patient and a healthy control were compared. PCR amplification of cDNA from exon 8 to exon 11, using appropriate primers, resulted in a shorter fragment in CS1EA1 compared to the control. Sequence analysis of the amplicon revealed that exon 9 is missing in the transcript of the CS1EA1 patient. At the protein level, skipping of exon 9 is predicted to shift the reading frame leading to the emergence of a premature stop codon, eight amino acid after (p.Ala240Glyfs\*8), and therefore a protein of only 246aa in length (instead of 396aa) (Fig. 4).

## -Cellular response to UV in CS patients

UV irradiation tests showed that 6 cell lines derived from CS patients, exhibited reduced response to UV compared to healthy controls. Response to increasing doses (0–15 J/m<sup>2</sup>) of UV radiation was first assessed by RNA recovery synthesis (RRS) that displayed strongly reduced RNA synthesis in all CS samples compared to the healthy control, with a better response for CS6EA1. As expected, cells derived from CS patients displayed unscheduled DNA synthesis (UDS) comparable to healthy controls (whereas the XP positive control patient had low UDS levels). Altogether these results indicate defective capacity to repair UV induced DNA damage on the transcribed strand in CS patients, including those that do not display abnormal sensitivity to sunlight (Fig. 4), in agreement with previous findings (5, 16) .

## Discussion

### Mutations in eight CS patients

Essentially two genes have been associated with CS, namely *ERCC6* in 68% and *ERCC8* in 32% of patients (6). The situation is possibly reversed in Tunisia and Arab countries, where *ERCC8* mutations seem to be more frequent (5, 13, 14, 17, 18). The present study expands the clinical spectrum and increases the relevance of two mutations in the CSA subtype. These genetic defects seem to be specific to the Tunisian and North African population, as they have not been reported elsewhere, at least to date. Indeed, since the first description of CS by Dr. Cockayne in 1936, only eight patients have been reported in the Tunisian population: two siblings have one of the mutation described here (c.598\_600delinsAA) (12) (13), two other siblings have a private mutation (c.400-2A > G) in *ERCC8* (18), and four more CS patients have been clinically and biochemically characterized but the mutations have not been identified (19, 20) .

In six patients of our Cohort, Sanger sequencing identified a recurrent *ERCC8* mutation, namely the homozygous mutation c. 598\_600delinsAA p.Tyr200Lysfs\*12, which was previously identified in two Tunisian siblings (12, 13). Indels are the second most common class of mutation in the human genome (21), and often involve domains with repetitive sequences (22). *ERCC8* encodes a 44 kDa protein, CSA that contains 7 WD40 domains each of which is constituted by several WD repeats [tryptophan (Trp, W), aspartic acid (Asp, D)]. The c. 598\_600delinsAA variation in *ERCC8* patients could lead to a nonsense-mediated mRNA decay (NMD). In detail, the alteration of the fourth evolutionarily conserved amino-acid residue in the WD4 repeated motif may result in a premature stop codon after 12 aminoacids (AA). The WD motifs are required for the construction of the beta-propeller structure, which is important for protein complex formation and interactions of CSA with transcription and repair factors DDB1, RNA polymerase II, TFIIH (10, 23).

The relatively larger proportion of *ERCC8* defects, and in particular the c.598\_600delinsAA mutation, in Tunisian patients can be attributed to a founder effect. Further investigations including haplotype analysis are required to verify whether this is the case. Interestingly, one of the six patients has Algerian ancestries suggesting that this variation is a founder mutation in North Africa.

Furthermore, via targeted gene sequencing, we detected in two patients (CSEA1 and CS1EA2) a variation that has not been previously reported in the Tunisian population, i.e. c.843 + 1G > C. This homozygous mutation leads to the abolition of the consensus donor splice site in intron 9, generating a novel splice event, and leading to exon 9 skipping in the *ERCC8* gene and the emergence of a premature stop codon. The donor splice mutation detected in patients from the CS1 family leads to a shorter protein lacking the last two WD40 domains, which may affect the function of this protein. This variant co-segregated in the CS1 family members, an additional argument indicating that this variant is causal of the CS disorder in these patients.

The c.843 + 1G > C variation has been already described in a CS patient from Lebanon (14) but the conclusions on the consequence of this variant on the transcript differ in our study. Indeed, Chelby et al suggested that intron 9 was present, because PCR failed to amplify a fragment that contained this exon. However, in our understanding the primers used in this PCR were located exactly in exon 9. In this case the reason for lack of amplification was the absence of this exon, in agreement with our findings. Moreover, the presence of intron 9 was not further demonstrated. In addition, the amplification obtained with primers 1 englobing exon 9 to intron 9 could be due to contaminating DNA acting as a competitor in the PCR reaction (24), if samples were not treated with DNase before RT-PCR, as we did. Moreover, this transcript could be poorly expressed and therefore was not detected in the previous study. This mutation ultimately results in the same consequences as the c.843 + 2T > G and c.843 + 5G > C variations that have been also suggested to alter donor splice site and lead to a premature stop codon p.Ala240Glyfs\*8 (12, 25) .

### Remarkable clinical features and lack of clinical photosensitivity

Each of the reported cases in the present study displays each distinct clinical features. It is worth to note that some patients (CS1EA1, CS11 and CS16) suffered from intra-uterine growth retardation. This clinical feature is more frequently associated with the severe form of CS-type II, which is usually linked to mutation in *ERCC6*. Conversely, in our study all patients had the CS-A form (mutation of *ERCC8*), which is normally less frequent (14% of cases) (16, 26). Other

clinical manifestations as microcephaly and ataxia at birth are not unique for CS and have been described also in mitochondria-associated diseases, which makes the CS diagnosis more difficult at early stages.

Previous studies reported CS patients that do not present clinical photosensitivity, as in Tunisian, Turkish, Italian, and Moroccan populations (5, 19, 27, 28). Therefore, cutaneous photosensitivity was classified as a minor criterion in the diagnosis of CS that appears only in about 75% of patients and was not correlated with the type of genetic defect in the TCR-NER pathway. Our data, with the two siblings from the CS1 family (mutation c.843 + 1G > C), as well as the CS11 patient mutation c.598\_600delinsAA not displaying clinical photosensitivity confirm that this defect is not an essential criterium for CS. The absence of clinical photosensitivity required assessing the repair of UV-induced DNA damage by TC-NER in primary fibroblasts from these patients. Indeed, since 1977 it has been shown that fibroblasts from CS patients had increased sensitivity to UV irradiation (29). Conventional methods to assess TC-NER include RRS following UV damage that is impaired in CS (30), and unscheduled DNA synthesis that is not affected in these patients whereas it is in XP patients (31). When clinical photosensitivity is identified in CS, it remains very moderate compared to other forms of genodermatosis related to defects of the NER system.

Comparison between conventional mild phenotype CS patients and CS patients who did not show photosensitivity displayed no difference in RRS, which was low in both groups as compared to controls. This indicates that photosensitivity, even if not clinically visible, is present at the cellular level in CS. RRS following UV damage remains useful to confirm the diagnostic and is complementary to genetic investigations.

This further substantiate that Cockayne syndrome may not be accounted to the defective NER system alone. Indeed, variations in *ERCC6* and *ERCC8* genes were also associated with the UV sensitive syndrome (UVSS), a milder form clinically characterized by mild cutaneous symptoms. In UVSS patients, reduced RRS after UV radiations was also observed, indicating that despite TC-NER was impaired this defect did not lead to neurodegeneration or premature ageing typical of CS.

Lack of association between CS and clinical photosensitivity in some patients suggests that other or additional mechanisms than the DNA repair defect are involved in the etiology of CS. In this context, CS exhibit altered mitochondrial metabolism and an accumulation of oxidative stress at the cellular level (32, 33). CSA and CSB are indeed multifunctional proteins that are involved in several processes in addition to DNA repair (34, 35).

## Heterogeneous clinical features in patients with the same mutation and siblings

CS is a clinically heterogeneous disease and is caused by a large number of distinct mutations in *ERCC6* or *ERCC8* (5, 36). For comparison, other monogenic diseases, for instance the Hutchinson-Guilford progeria syndrome (HGPS) is due to a single point mutation that blocks the physiological processing of the Laminin A protein (37). Conversely, 38 pathogenic variants have been described just for *ERCC8/CSA* and which concern totally 84 CS patients (36). Since genotype/phenotype correlation remains elusive, relevant information may originate from the study and the assessment of their clinical symptoms in multiple patients and, when available, siblings carrying the same mutation. However, this situation is rather infrequent and only three other cases of siblings as well as patients carrying the same mutations (13, 38) have been described in CS. The present study that reports a detailed clinical characterization of six patients, including two siblings that carry the same mutation as well as two siblings carrying a second mutation, represents a powerful data set to address this question.

The six patients carrying the c.598\_600delinsAA mutation shared common characteristics: early age symptoms [0–24 months], prenatal abnormalities as microcephaly, cerebellar hypoplasia, oligohydramnios, and lower post-natal weight and height. They also displayed different combinations (presence/absence) of other defects like normal or low birth weight and height, ataxia, cataracts, dental abnormalities, hypomyelination, cerebellar atrophy, etc. Importantly, within this group the two CS6 siblings displayed remarkable phenotypic differences, like post-natal height, independent walking, dental abnormalities, and cryptorchidism.

Two siblings from the CS1 family (mutation c.843 + 1G > C) presented high levels of transaminase which are commonly observed in other CS patients reflecting a possible mild liver damage (4, 39). Moreover, the younger of the two patients displayed severe symptoms like the emergence of cataracts at an early age. Indeed, the presence of cataracts is normally associated with a worst probability of survival and death before the age of 7 for CS patients (40). Only one of the two siblings (CS1EA1, a male) showed prenatal microcephaly oligohydramnios and cataracts. Conversely, only the other sibling (CS1EA2, a female) showed bird-like nose dysmorphism, limb spasticity, ataxia, hair and dental abnormalities, cerebellar atrophy. These clinical differences in the context of the same mutation and, in the case of siblings also of comparable genetic background, underscore the large heterogeneity of CS clinical symptoms that is difficult to reconcile with a simple genotype/phenotype alteration, and the reason of which remains obscure.

It is important to note that the clinical heterogeneity of patients that share the same recurrent mutation increases the difficulty for clinicians to confirm the clinical diagnosis of this disease, and may generate confusion with pathologies that display related symptoms like those linked to mitochondrial etiopathology such as mitochondrial cytopathies. Moreover, the clinical heterogeneity in CS may represent a further challenge for treatments, which have not been developed for CS to date.

## Characteristics of the Tunisian cohort

We reported six patients with the same homozygous variation, including one of Algerian origin. This mutation was previously observed in two other Tunisian patients (41), which suggests that it is a founder mutation in the region. The CS6 siblings were born from a consanguineous marriage. Although the CS1 siblings were born from a non-consanguineous marriage, the emergence of the homozygous mutation, and thereby of CS, is likely due to the high rate of endogamy in this region. In Tunisia, the high rate of endogamy contributes to the increased risk (96.64%) of recessive diseases in isolated communities even without consanguinity (42).

The two siblings of the CS1 family harbor the same genetic variation as in a previously reported Lebanese patient, who also displayed a severe CS phenotype (14). North Africa's abundant prehistoric and historic cultural heritage has added to the diversity of the genetic pool of its population nowadays (43). This pool

originates from a combination of Middle Eastern, Sub-Saharan Africa and Western European genetic components. For instance, the two Tunisian CS1 patients described here share a variant with the Lebanese patient born from Druze parents, possibly dating back to a common ancestry.

## Conclusions

In the present work we report the largest cohort of patients with Cockayne syndrome-A in Tunisia to date, and enlarged the description of *ERCC8*/CSA variants globally. This study provides genetic, biochemical, and clinical data on siblings and multiple patients carrying the same *ERCC8*/CSA variant, underscoring the large heterogeneity of CS beyond the mutation. Although all CS-derived cells explored in this work had a DNA repair defect following UV exposure, some patients including those with a severe phenotype, did not show clinical photosensitivity. This finding confirms the notion that photosensitivity is not an essential clinical feature of this pathology, and further questions the mechanistic link between some clinical manifestations and the deficit of the DNA repair system.

A thorough clinical characterization in CS patients, in whom the deleterious effect of the identified mutations has been confirmed, should facilitate the early management of other patients in the future, and the establishment of a prenatal diagnosis. Moreover, thanks to the awareness of the families studied, an antenatal investigation was carried out three times for two consanguineous families at risk (two times for CS1 family and one time for CS6 family). Our study shows that collaboration between clinicians and researchers has an important impact on the follow-up of patients' families, mainly for the pathology of CS, a very severe disease which has no treatment to date.

## Methods

### Patients

Eight patients were recruited from the Department of Child Neurology (National Institute Mongi Ben Hmida de Tunis) in 2017–2019. These patients underwent neurological and general examination routine since 2017. Blood tests, metabolic tests, CT-scan and/or brain MRI and electrophysiological studies have been done for patients strongly suspected to be affected by Cockayne syndrome. Written informed consent was obtained from patients' parents as CS patients were minors. Blood and skin biopsies as well as genealogical data were collected. The study was approved by IPT (Institut Pasteur de Tunis) Biomedical Ethics Committee in Tunisia (reference 2017/31/I/LR16IPT05/V2), in accordance with the Declaration of Helsinki Principles.

### DNA extraction and quantification

Genomic DNAs were isolated from peripheral blood of patients and their parents using FlexiGene kit (Qiagen). DNA samples yield and purity were assessed using a Nanodrop Spectrophotometer (Thermo Scientific, Wilmington, USA).

### gDNA sequencing

Genetic studies started by screening for the recurrent *ERCC8* pathogenic variation already described in North African CS patients (NM\_000082.3 c.598\_600delinsAA p.Tyr200Lysfs\*12) using Sanger sequencing (F: 5' CAAGTGATGGACTTCACCTC 3' R:5' CTGCCTGAACATCCCTAATC 3'. *ERCC8* Exon 7 was amplified with the following primers set (F: 5' CCCTTTGAACTTATCACCTG 3' R: 5' CCTCTGTGCCCTAGACAAT 3') and sequenced using the ABI 3130 Genetic Analyzer (Applied Biosystems).

In absence of the recurrent variation, molecular screening of the patients was continued by next generation sequencing assay targeting 17 genes involved in NER pathway (*DDB2*, *ERCC1*, *ERCC2*, *ERCC3*, *ERCC4*, *ERCC5*, *ERCC6*, *ERCC8*, *GTF2H5*, *MPLKIP*, *PCNA*, *POLH*, *RNF113A*, *SMARCAL1*, *UVSSA*, *XPA*, and *XPC*). Regions of interest were captured using SureSelect QXT Agilent probes and libraries were sequenced on a NextSeq550 Illumina platform. For data analysis, home-made "STARK" and Polyweb (Université Paris Descartes) pipelines were used to detect both single nucleotide and copy number variations. Pathogenicity of the variants were tested using online prediction tools like MutationTaster (<http://www.mutationtaster.org/>), Sift (<https://sift.bii.a-star.edu.sg/>), Polyphen (<http://genetics.bwh.harvard.edu/pph2/>) MaxEnScan ([http://hollywood.mit.edu/burgelab/maxent/Xmaxentscan\\_scoreseq\\_acc.html](http://hollywood.mit.edu/burgelab/maxent/Xmaxentscan_scoreseq_acc.html)) and previously publically available Human Splicing Finder version 3.1\_2017 (<http://www.umd.be/HSF/>). The presence of a variation in a proband was confirmed by Sanger sequencing as well as segregation analysis.

### Primary dermal fibroblasts

All dermal fibroblasts were obtained from skin biopsies. Cells were grown at 37°C in 5 % CO<sub>2</sub> humidified atmosphere in Dulbecco's modified Eagle medium (DMEM) (1g/L glucose) w/GLUTAMAX (Life Technologies, Gibco) supplemented with 10% of fetal calf serum (Gibco) and 1% penicillin/streptomycin (Gibco). All fibroblasts primary cultures were assessed at comparable passage number (passage number 3 to 4).

#### Analysis of *ERCC8* cDNA from primary dermal fibroblasts cultures

Total RNA from 10<sup>6</sup> of dermal fibroblasts was isolated using Trizol reagent (Sigma-Aldrich) according to the manufacturer's instruction. To avoid contamination with genomic DNA, samples were treated with DNase (Invitrogen). The cDNA was synthesized from 1 µg of RNA using oligo dT primers with the Superscript Reverse transcriptase II (Invitrogen), according to the manufacturer's instructions. For the analysis of the region of interest, polymerase chain reaction was used to amplify the cDNA spanning exon 8 to exon 12 (F:5' GTGAGAAGAGCATCAGGATG3' R:5' CCAGAATGTTGCAGTCTCTG3'). Which was assessed in agarose gel and compared to healthy for amplicon's length and further analyzed via Sanger sequencing.

### DNA repair essay

Responses to UV irradiation in primary fibroblasts were evaluated through unscheduled DNA synthesis (UDS) and recovery of RNA synthesis (RRS) after DNA damage, as described (44–46). Briefly, cells were plated on coverslips in 6-well plates and exposed to UV-C doses at 0, 5, 10 and 15 J/m<sup>2</sup>. *De novo* DNA synthesis was measured via incorporation of 5-ethynyl-2'-deoxyuridine (EdU) after UV irradiation in 6 CS patient fibroblasts (CS1EA1, CS1EA2, CS2, CS6EA1, CS6EA2, CS7), one healthy donor control, one Xeroderma pigmentosum and one Cockayne syndrome (affected DNA repair) controls. RNA detection was performed by irradiating primary culture of fibroblasts with UV-C doses (0, 6, 12, and 20 J/m<sup>2</sup>). 5-ethynyl uridine (5-EU) incorporation was assessed after 24 hours of recovery from the UV exposure. The images were processed and analyzed with Image J for 50 randomly selected cells, originating from three independent experiments, and the average nuclear fluorescence intensity was calculated.

## Declarations

## Ethic approval and consent for publication

The study was approved by Institute Pasteur Ethics Committee in Tunisia (reference 2017/31/I/LR16IPT05/V2), in accordance with the Declaration of Helsinki Principles. Written informed consent was obtained from the legal tutor of all patients for genetic investigation and publication.

## Availability of data and materials

All processed data have been provided in the manuscript. Raw data, generated for this study could be provided by the corresponding author upon reasonable request.

## Competing interests

The authors declare that they have no competing interests

## Funding statement

This work was supported by the Ministry of Higher Education and Scientific Research (LR16IPT/05), the “Programmes Transversaux de Recherche” project (PTR\_Rejuvenage 2017-2019) and the “Projet Collaboratif Interne (PCI\_Ageing 2019\_2021).

## Author contribution

A.C. did genetic investigation experiments, cell cultures, data analysis and drafted the manuscript.

I.K. did clinical investigation of patients and family members and drafted the manuscript.

N.C. did targeted gene sequencing experiments and data interpretations.

C.O. did UDS, RRS experiments and analysis.

S.B. did skin biopsies.

K.Z, B.M, R.M. helped in primary skin fibroblasts expansion and/or patients recruitment

S.A. contributed in genetic investigation.

V.L and I.T. did revisions for clinical findings for CS patients

H.Y.Y and MR. did study concept, design and critical revision of the manuscript.

H.Y.Y. supervised the study.

## Acknowledgements

We would like to thank the patients and their families for their collaboration.

## References

1. Schärer OD. Chemistry and biology of DNA repair. *Angewandte Chemie (International ed in English)*. 2003;42(26):2946-74.
2. Spivak G. Nucleotide excision repair in humans. *DNA Repair*. 2015;36:13–8.
3. Fuss JO, Cooper PK. DNA Repair: Dynamic Defenders against Cancer and Aging. *PLOS Biology*. 2006;4(6):e203.
4. Nance MA, Berry SA. Cockayne syndrome: review of 140 cases. *Am J Med Genet*. 1992;42(1):68–84.

5. Calmels N, Botta E, Jia N, Fawcett H, Nardo T, Nakazawa Y, et al. Functional and clinical relevance of novel mutations in a large cohort of patients with Cockayne syndrome. *J Med Genet.* 2018;55(5):329–43.
6. Wilson BT, Stark Z, Sutton RE, Danda S, Ekbote AV, Elsayed SM, et al. The Cockayne Syndrome Natural History (CoSyNH) study: clinical findings in 102 individuals and recommendations for care. *Genet Med.* 2016;18(5):483–93.
7. Kleijer WJ, Laugel V, Berneburg M, Nardo T, Fawcett H, Gratchev A, et al. Incidence of DNA repair deficiency disorders in western Europe: Xeroderma pigmentosum, Cockayne syndrome and trichothiodystrophy. *DNA Repair.* 2008;7(5):744–50.
8. Zghal M, El-Fekih N, Fazaa B, Fredj M, Zhioua R, Mokhtar I, et al. [Xeroderma pigmentosum. Cutaneous, ocular, and neurologic abnormalities in 49 Tunisian cases]. *La Tunisie medicale.* 2005;83(12):760–3.
9. Groisman R, Polanowska J, Kuraoka I, Sawada J-i, Saijo M, Drapkin R, et al. The ubiquitin ligase activity in the DDB2 and CSA complexes is differentially regulated by the COP9 signalosome in response to DNA damage. *Cell.* 2003;113(3):357–67.
10. Fischer ES, Scrima A, Bohm K, Matsumoto S, Lingaraju GM, Faty M, et al. The molecular basis of CRL4DDB2/CSA ubiquitin ligase architecture, targeting, and activation. *Cell.* 2011;147(5):1024–39.
11. Lake RJ, Fan HY. Structure, function and regulation of CSB: a multi-talented gymnast. *Mech Ageing Dev.* 2013;134(5–6):202–11.
12. Laugel V, Dalloz C, Durand M, Sauvanaud F, Kristensen U, Vincent MC, et al. Mutation update for the CSB/ERCC6 and CSA/ERCC8 genes involved in Cockayne syndrome. *Hum Mutat.* 2010;31(2):113–26.
13. Blin-Rochemaure N, Allani-Essid N, Carlier R, Laugel V, Quijano-Roy S. [The place of neuropathy in the early diagnosis of Cockayne syndrome: Report on two siblings]. *Arch Pediatr.* 2017;24(4):353–9.
14. Chebly A, Corbani S, Abou Ghoch J, Mehawej C, Megarbane A, Chouery E. First molecular study in Lebanese patients with Cockayne syndrome and report of a novel mutation in ERCC8 gene. *BMC Med Genet.* 2018;19(1):161.
15. Desmet F-O, Hamroun D, Lalonde M, Collod-Bérout G, Claustres M, Bérout C. Human Splicing Finder: an online bioinformatics tool to predict splicing signals. *Nucleic acids research.* 2009;37(9):e67-e.
16. Laugel V. Cockayne syndrome: the expanding clinical and mutational spectrum. *Mech Ageing Dev.* 2013;134(5–6):161–70.
17. Khayat M, Hardouf H, Zlotogora J, Shalev SA. High carriers frequency of an apparently ancient founder mutation p. Tyr322X in the ERCC8 gene responsible for Cockayne syndrome among Christian Arabs in Northern Israel. *American Journal of Medical Genetics Part A.* 2010;152(12):3091–4.
18. Ben Chehida A, Ghali N, Ben Abdelaziz R, Ben Moussa F, Tebib N. Renal Involvement in 2 Siblings With Cockayne Syndrome. *Iran J Kidney Dis.* 2017;11(3):253–5.
19. Tinsa F, Bellalah M, Brini I, Bousnina D, Lehmann A, Boussetta K, et al. Infantile onset of Cockayne syndrome without photosensitivity in a Tunisian girl. *La Tunisie medicale.* 2009;87(12):877–9.
20. Kaissi A, Safi H, Ghachem M, Hendaoui L, Chehida F. Congenital dysplastic hips, spinal column abnormalities, fractures and progressive neurological manifestations in Tunisian family with cockayne syndrome. *Annals of African Medicine.* 2005;4(2):83–7.
21. Mullaney JM, Mills RE, Pittard WS, Devine SE. Small insertions and deletions (INDELs) in human genomes. *Hum Mol Genet.* 2010;19(R2):R131-6.
22. Taylor MS, Ponting CP, Copley RR. Occurrence and Consequences of Coding Sequence Insertions and Deletions in Mammalian Genomes. *Genome Res.* 2004;14(4):555–66.
23. Saijo M. The role of Cockayne syndrome group A (CSA) protein in transcription-coupled nucleotide excision repair. *Mech Ageing Dev.* 2013;134(5–6):196–201.
24. Ivarsson K, Weijdegård B. Evaluation of the effects of DNase treatment on signal specificity in RT-PCR and in situ RT-PCR. *Biotechniques.* 1998;25(4):630–8.
25. Wang X, Huang Y, Yan M, Li J, Ding C, Jin H, et al. Molecular spectrum of excision repair cross-complementation group 8 gene defects in Chinese patients with Cockayne syndrome type A. *Scientific reports.* 2017;7(1):13686.
26. Spitz MA, Severac F, Obringer C, Baer S, Le May N, Calmels N, et al. Diagnostic and severity scores for Cockayne syndrome. *Orphanet Journal of Rare Diseases.* 2021;16(1):63.
27. Colella S, Nardo T, Mallery D, Borrone C, Ricci R, Ruffa G, et al. Alterations in the CSB gene in three Italian patients with the severe form of Cockayne syndrome (CS) but without clinical photosensitivity. *Human molecular genetics.* 1999;8(5):935–41.
28. Sonmez FM, Celep F, Ugur SA. Severe Form of Cockayne Syndrome With Varying Clinical Presentation and No Photosensitivity in a Family. *J Child Neurol.* 2006;21(4):333–7.
29. Schmickel R, Chu E, Trosko J, Chang C. Cockayne syndrome: a cellular sensitivity to ultraviolet light. *Pediatrics.* 1977;60(2):135–9.
30. Mayne LV, Lehmann AR. Failure of RNA synthesis to recover after UV irradiation: an early defect in cells from individuals with Cockayne's syndrome and xeroderma pigmentosum. *Cancer research.* 1982;42(4):1473–8.
31. Hoar DI, Waghorne C. DNA repair in Cockayne syndrome. *Am J Hum Genet.* 1978;30(6):590–601.
32. Scheibye-Knudsen M, Croteau DL, Bohr VA. Mitochondrial deficiency in Cockayne syndrome. *Mech Ageing Dev.* 2013;134(5–6):275–83.
33. Chatre L, Biard DS, Sarasin A, Ricchetti M. Reversal of mitochondrial defects with CSB-dependent serine protease inhibitors in patient cells of the progeroid Cockayne syndrome. *Proceedings of the National Academy of Sciences.* 2015;112(22):E2910-E9.
34. D'Errico M, Pascucci B, Iorio E, Van Houten B, Dogliotti E. The role of CSA and CSB protein in the oxidative stress response. *Mech Ageing Dev.* 2013;134(5–6):261–9.

35. Okur MN, Lee J-H, Osmani W, Kimura R, Demarest TG, Croteau DL, et al. Cockayne syndrome group A and B proteins function in rRNA transcription through nucleolin regulation. *Nucleic acids research*. 2020;48(5):2473–85.
36. Vessoni AT, Guerra CCC, Kajitani GS, Nascimento LLS, Garcia CCM. Cockayne Syndrome: The many challenges and approaches to understand a multifaceted disease. *Genetics and molecular biology*. 2020;43(1).
37. Piekawowicz K, Machowska M, Dzianisava V, Rzepecki R. Hutchinson-Gilford Progeria Syndrome-Current Status and Prospects for Gene Therapy Treatment. *Cells*. 2019;8(2):88.
38. Schalk A, Greff G, Drouot N, Obringer C, Dollfus H, Laugel V, et al. Deep intronic variation in splicing regulatory element of the ERCC8 gene associated with severe but long-term survival Cockayne syndrome. *Eur J Hum Genet*. 2018;26(4):527–36.
39. Natale V. A comprehensive description of the severity groups in Cockayne syndrome. *Am J Med Genet A*. 2011;155A(5):1081–95.
40. Karikkineth AC, Scheibye-Knudsen M, Fivenson E, Croteau DL, Bohr VA. Cockayne syndrome: Clinical features, model systems and pathways. *Ageing Res Rev*. 2017;33:3–17.
41. Blin-Rochemaure N, Allani-Essid N, Carlier R, Laugel V, Quijano-Roy S. Place de la neuropathie dans le diagnostic précoce du syndrome de Cockayne: à propos de deux cas dans une fratrie. *Archives de Pédiatrie*. 2017;24(4):353–9.
42. Ben Halim N, Nagara M, Regnault B, Hsouana S, Lasram K, Kefi R, et al. Estimation of Recent and Ancient Inbreeding in a Small Endogamous Tunisian Community Through Genomic Runs of Homozygosity. *Ann Hum Genet*. 2015;79(6):402–17.
43. Romdhane L, Mezzi N, Hamdi Y, El-Kamah G, Barakat A, Abdelhak S. Consanguinity and inbreeding in health and disease in north African populations. *Annu Rev Genom Hum Genet*. 2019;20:155–79.
44. Nakazawa Y, Yamashita S, Lehmann AR, Ogi T. A semi-automated non-radioactive system for measuring recovery of RNA synthesis and unscheduled DNA synthesis using ethynyluracil derivatives. *DNA Repair*. 2010;9(5):506–16.
45. Jia N, Nakazawa Y, Guo C, Shimada M, Sethi M, Takahashi Y, et al. A rapid, comprehensive system for assaying DNA repair activity and cytotoxic effects of DNA-damaging reagents. *nature protocols*. 2015;10(1):12–24.
46. Le May N, Calmels N, Abiayad Y, Boukli L, Semer M, Serradj A, et al. Xeroderma pigmentosum groups C and A in Algerian patients with deregulation of both transcription and DNA repair. *Journal of Case Reports and Studies*. 2018;6(4).

## Figures

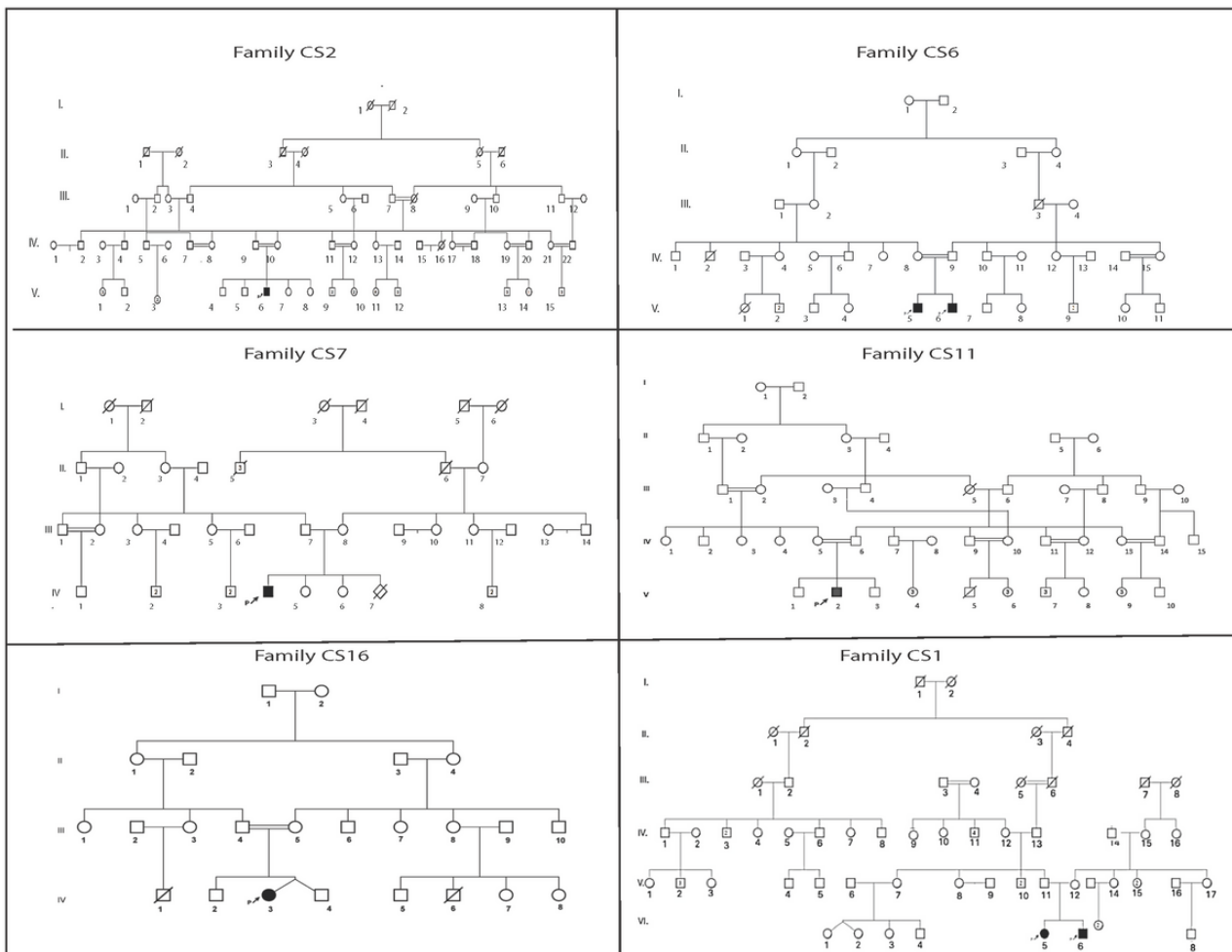


Figure 1

Pedigree of the six unrelated Tunisian families. The studied proband is indicated with an arrow.

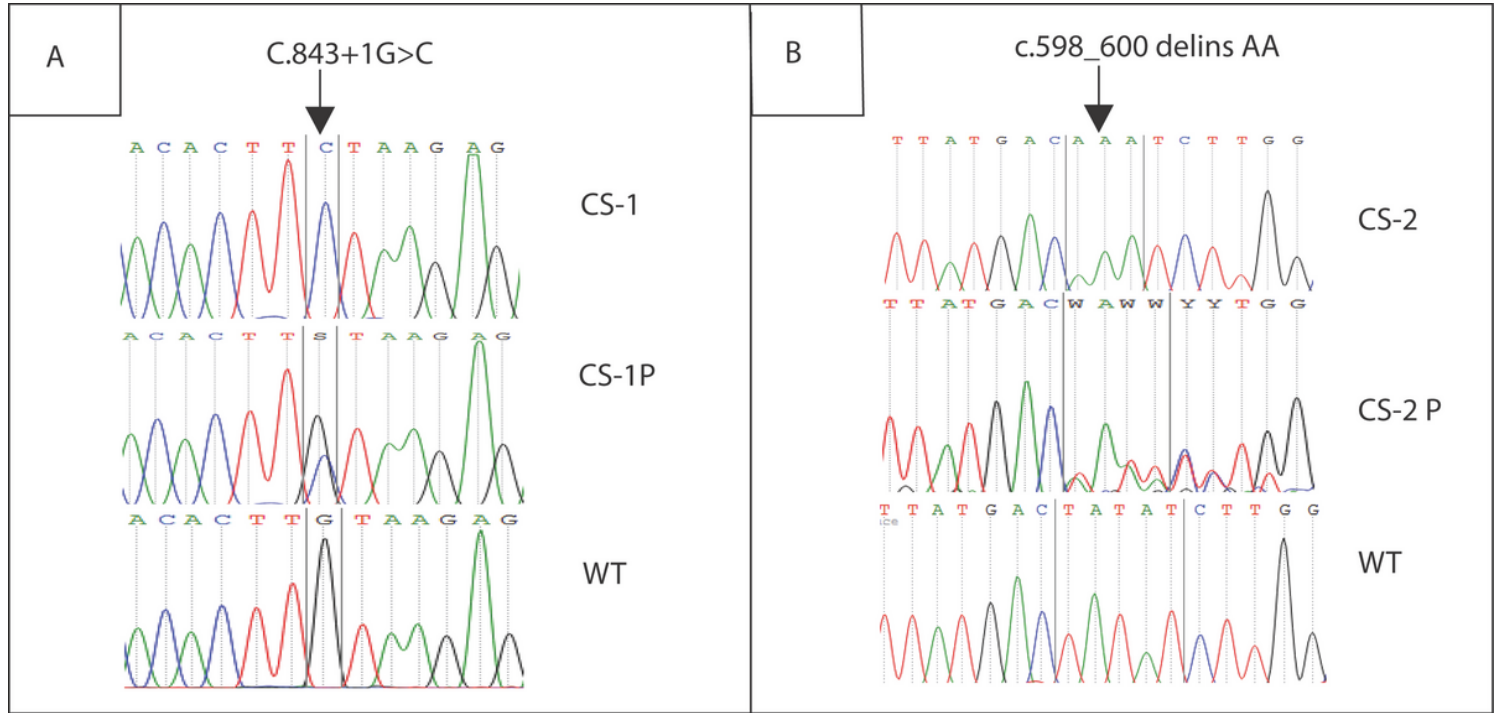
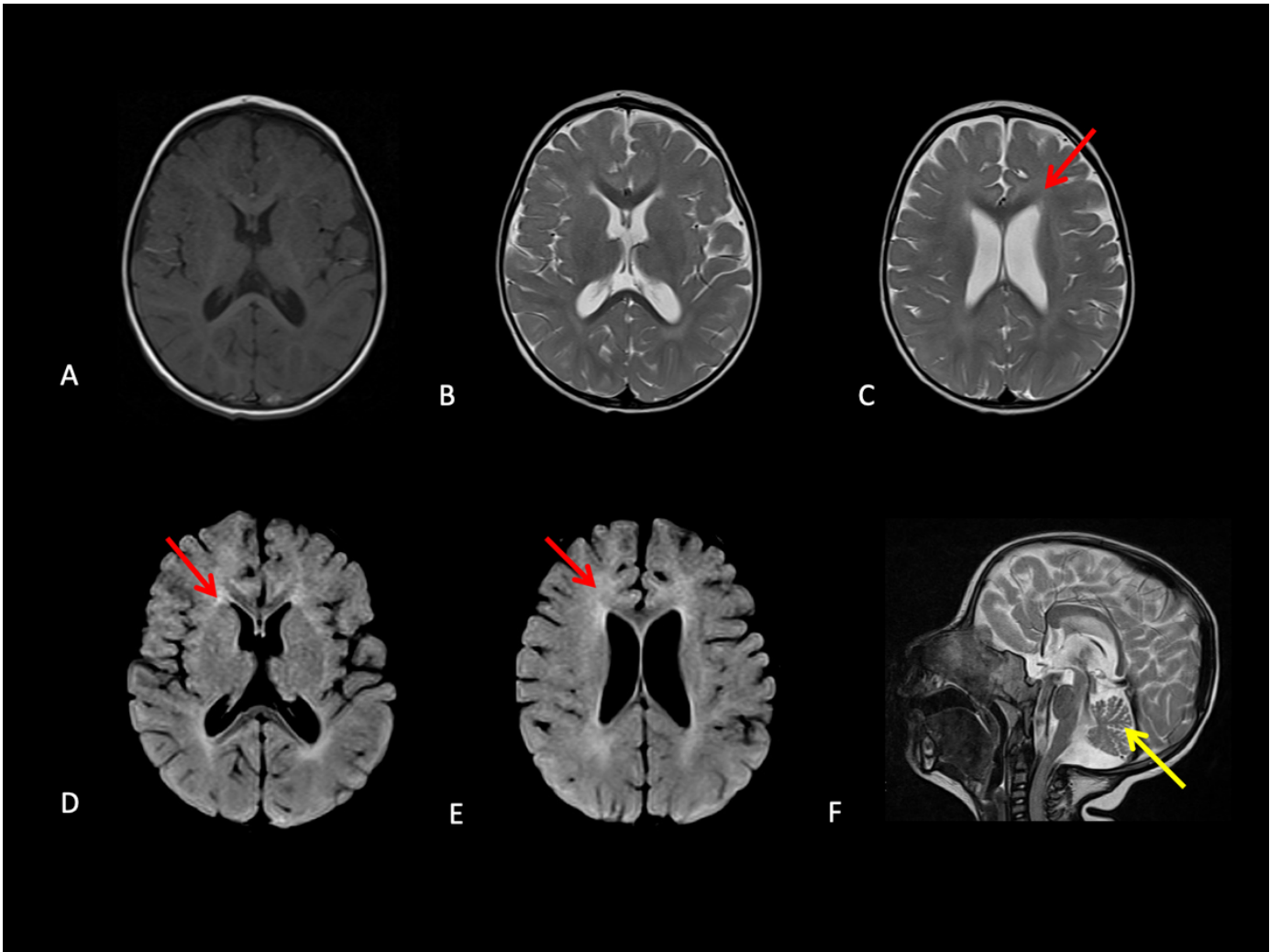


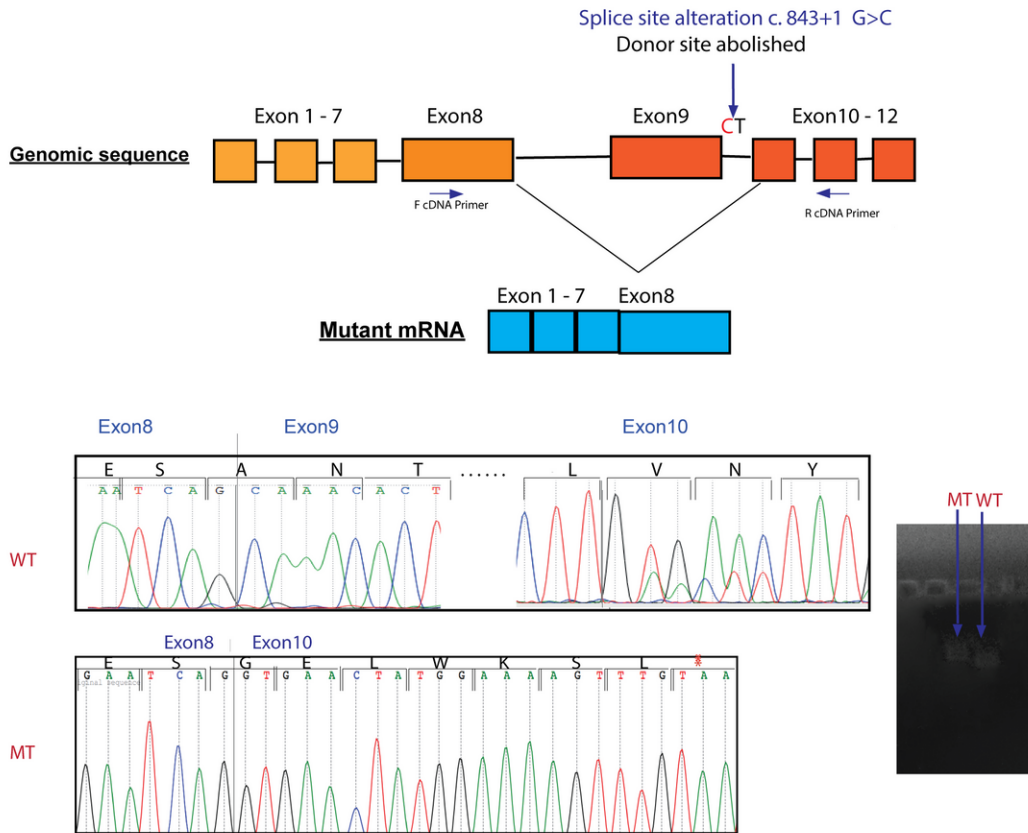
Figure 2

Genetic analysis of genomic DNA. Electropherogram showing: (A) the splice site mutation (c.843+1 G>C) in the ERCC8 gene in CS-1 family (patient CS-1 and parent CS-1P) and (B) the mutation (c.598\_600delinsAA) in the ERCC8 gene in CS-2 family (patient CS-2 and parent CS-2P), compared to WT.

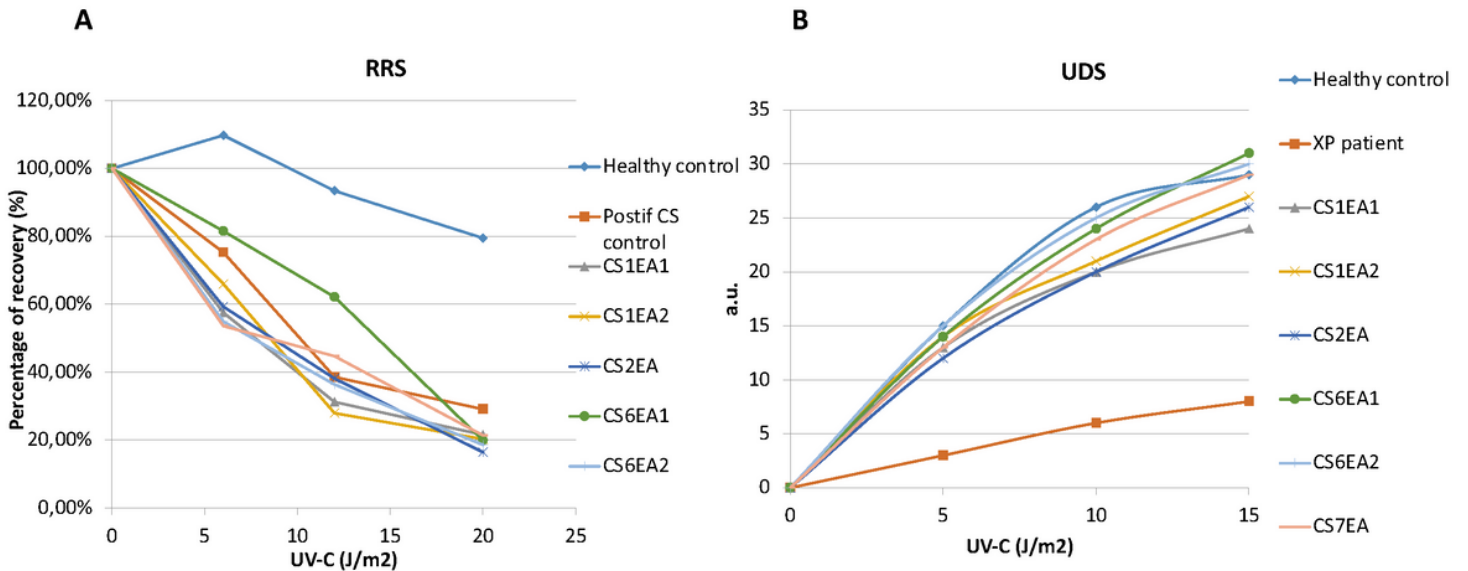


**Figure 3**  
MRI image of CS7. (A) Axial T1 weighted-image, (B, C) axial T2 weighted-images, and (D, E) axial FLAIR weighted-images showing isointensity of periventricular white matter on T1, and hyperintensity on T2. FLAIR is suggestive of hypomyelinating leukodystrophy (red arrows). (F) Sagittal T2 weighted-image showing cerebellar atrophy (yellow arrow).





**Figure 4**  
 CSA splicing alterations. Upper panel, schematic representation of the ERCC8 gene with aberrant skipping of exon 9 as a result of the c.843+1G>C mutation. Lower panel, sequencing of the mutant transcript (MT), which confirmed the aberrant splicing event compared to the wild type (WT); the stop codon in the mutant is indicated by an asterisk.



**Figure 5**

Response of UV radiation in fibroblasts from six CS Tunisian patients. (A) RRS 24h after UV irradiation expressed in percentage of recovery after EdU incorporation showing the defect of RNA synthesis after UV exposure in CS fibroblasts. (B) Unscheduled DNA repair synthesis (UDS) expressed in arbitrary units (a.u) of EdU fluorescence intensity. CS patients show a normal level of unscheduled DNA synthesis.

## Supplementary Files

This is a list of supplementary files associated with this preprint. Click to download.

- [ChikhaouietaFigureS1.tif](#)